

Ulcerative colitis and Crohn's disease

An overview of
the diseases and
their treatment



Publisher

FALK FOUNDATION e.V.



Leinenweberstr. 5
79108 Freiburg
Germany

www.falkfoundation.org

© 2018 Falk Foundation e.V.
All rights reserved.

30th edition 2018

Ulcerative colitis and Crohn's disease

An overview of
the diseases and
their treatment

Authors:

Prof. Dr. J. Schölmerich
Germanenstr. 8b
65719 Hofheim
Germany

Prof. Dr. Dr. G. Rogler
Klinik für Gastroenterologie
und Hepatologie
Universitätsspital Zürich
Rämistr. 100
8091 Zürich
Switzerland

H.H. Herfarth, M.D.
Professor of Medicine
Department of Medicine
Division of Gastroenterology and
Hepatology
University of North Carolina
School of Medicine
4151 Bioinformatics Building
130 Mason Farm Road
Chapel Hill, NC 27599-7080
USA

Associated authors of the 1st–3rd editions
Prof. Dr. A. Fürst, Dr. P. Hoppe-Seyler,
Prof. Dr. M. Lausen

Table of Contents

Preface	5
The names: Ulcerative colitis – Crohn’s disease	7
The digestive tract.	9
Symptoms	12
The bowel	
Other organs	
Ulcerative colitis	
Crohn’s disease	
Methods of examination	17
Physical examination	
Laboratory tests	
Ultrasound	
Endoscopy	
Gastroscopy	
Colonoscopy	
Proctoscopy	
Radiological examinations	
Magnetic resonance imaging (MRI)	
Computed tomography (CT)	
Capsule endoscopy	
Double balloon endoscopy	
Endosonography	
Follow-up studies	
Causes	30
Bowel diseases	
Associated conditions	
Complications	

Treatment	34
Ulcerative colitis	34
• Drugs	
• Side effects	
• Surgery	
• Diet	
Crohn's disease	41
• Drugs	
• Nutritional therapy	
• Surgery	
• Deficiency syndromes	
Psychotherapy	45
Special problems	46
Course of the disease	
Fistulae	
Osteoporosis	
The risk of cancer	
Psychological burden	
Self-help groups	
Ability to work and professional life	
Leisure	
Sex and partnership	
Reproduction and genetic factors	
Pregnancy	
The artificial bowel outlet	
What patients need to bear in mind	55
Glossary	57

Preface

Every chronic disease represents a difficult challenge – for the patients, their family and for the physicians managing their care. This is particularly true when the causes of the disease are only partially understood and when the disease is so rare that the typical family doctor may only treat a few cases in his/her primary care practice. About one in every 130–250 people in Central Europe suffer from inflammatory bowel disease. A person confronted with a diagnosis of inflammatory bowel disease or IBD usually first feels a great deal of uncertainty: What does it mean to have a chronic disease? What course can I expect the disease to take? How will it affect my life? What limitations will I have? These are the questions that those who receive such a diagnosis are forced to wrestle with. A survey of patients with inflammatory bowel disease showed that the majority feel that they do not have sufficient information regarding their disease. While no brochure can replace face-to-face discussions with a physician, every additional source of information can be useful. A brochure may be of particular help in assisting you in converting your uncertainties and anxiety into concrete questions that can then be discussed with your physician.

The present brochure is intended to be just such a source of information. However, if you are not satisfied with this brochure or you find that it leaves your questions unanswered, please let us know. Your opinions are important to us and will help us to improve this brochure in future editions.

J. Schölmerich, G. Rogler, H. Herfarth



The names: Ulcerative colitis – Crohn’s disease

You or a member of your family has been confronted with a diagnosis of inflammatory bowel disease or IBD. In most cases, this means either ulcerative colitis or Crohn’s disease. At first, these names may seem strange and you probably wonder what they mean. Both refer to chronic inflammation of the mucosal lining of the intestine or bowel, though each has quite specific characteristics.

What do the names mean?

The use of different names is based on the fact that the disease is often named according to the portion of the bowel it affects and which becomes inflamed. The chart on page 11 shows the organs of the digestive tract and gives the names of the various segments. The **small bowel** is usually 3–5 m long, while the **large bowel** is



Dr. Burrill B. Crohn

usually 1.5 m long. A distinction is made between the two main forms of inflammatory bowel disease: The first type is **ulcerative colitis**, an inflammation (“-itis”) that only affects the large bowel (**colon**), and is associated with the formation of ulcers (**hence “ulcerative”**). If the disease only affects the rectum, then it is known as **proctitis** (proctos = rectum).

The second disease type is named after one of the people who discovered it, the American gastroenterologist **Burrill B. Crohn** – hence the name **“Crohn’s disease”**. This disease can affect all sections of the digestive tract, from the mouth to the anus. Depending on the exact bowel segments affected, the terms used include Crohn’s ileitis, Crohn’s colitis, Crohn’s ileocolitis, or Crohn’s enteritis.

The digestive tract

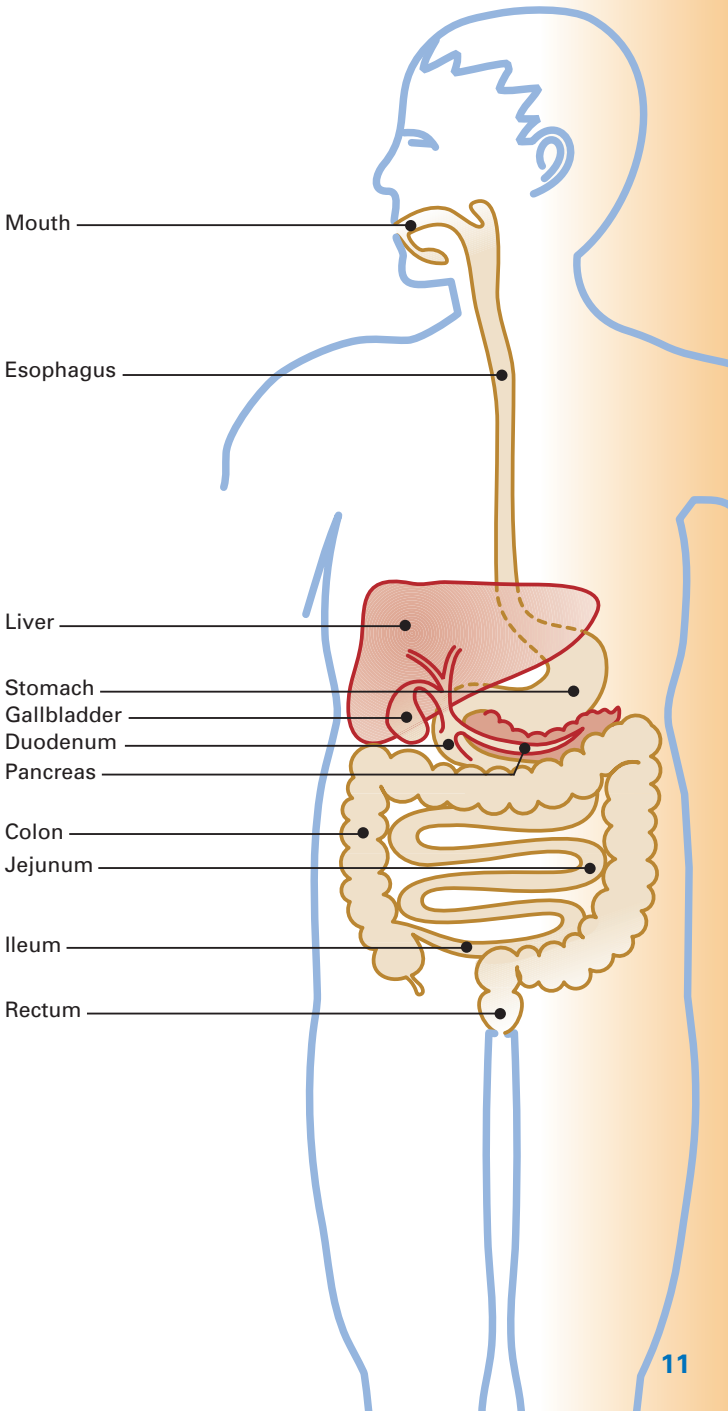
What you should know about the normal digestive tract:

The **digestive tract** begins in the mouth. Here, the food is chewed and mixed with saliva, lubricating and partially digesting it. Once swallowed, the food passes into the esophagus, a muscular tube, whose walls move in wave-like patterns propelling the food downward into the stomach. In the stomach, the food is mixed with gastric juices, consisting of acid, mucus and various enzymes, which begin the breakdown of proteins. In the duodenum, the food is further mixed with secretions from the pancreas that contain other digestive enzymes, and with bile. The main role of bile is to provide bile acids that help to digest fats. In **ulcerative colitis**, these functions may be disrupted in very rare cases (due to a disease of the bile ducts occurring at the same time), and they are sometimes disrupted in **Crohn's disease**.

Fats, protein breakdown products, sugars, fat-soluble vitamins (A, D, E, K), and some trace elements and minerals are absorbed in the **middle segment of the small bowel (jejunum)**. Vitamin B₁₂ and bile acids are absorbed into the body in the **final segment of the small bowel (ileum)**. This latter function is sometimes disrupted in patients with **Crohn's disease**, while dysfunctions of the jejunum occur less often. The insufficient absorption of bile acids in the ileum, however, may adversely affect the digestion of fats and fat-soluble vitamins in the jejunum.

The main task of the **large bowel (colon)** is to absorb water and minerals into the body and to thicken the stool. The stool is then formed in the **final part of the**

large bowel (sigmoid colon + rectum). Using the muscles of the sphincter, the **anus** holds back the stool until a voluntary bowel movement occurs. These functions may be adversely affected in both ulcerative colitis and Crohn's disease, potentially resulting in involuntary passage of gas or stool (incontinence).



Symptoms

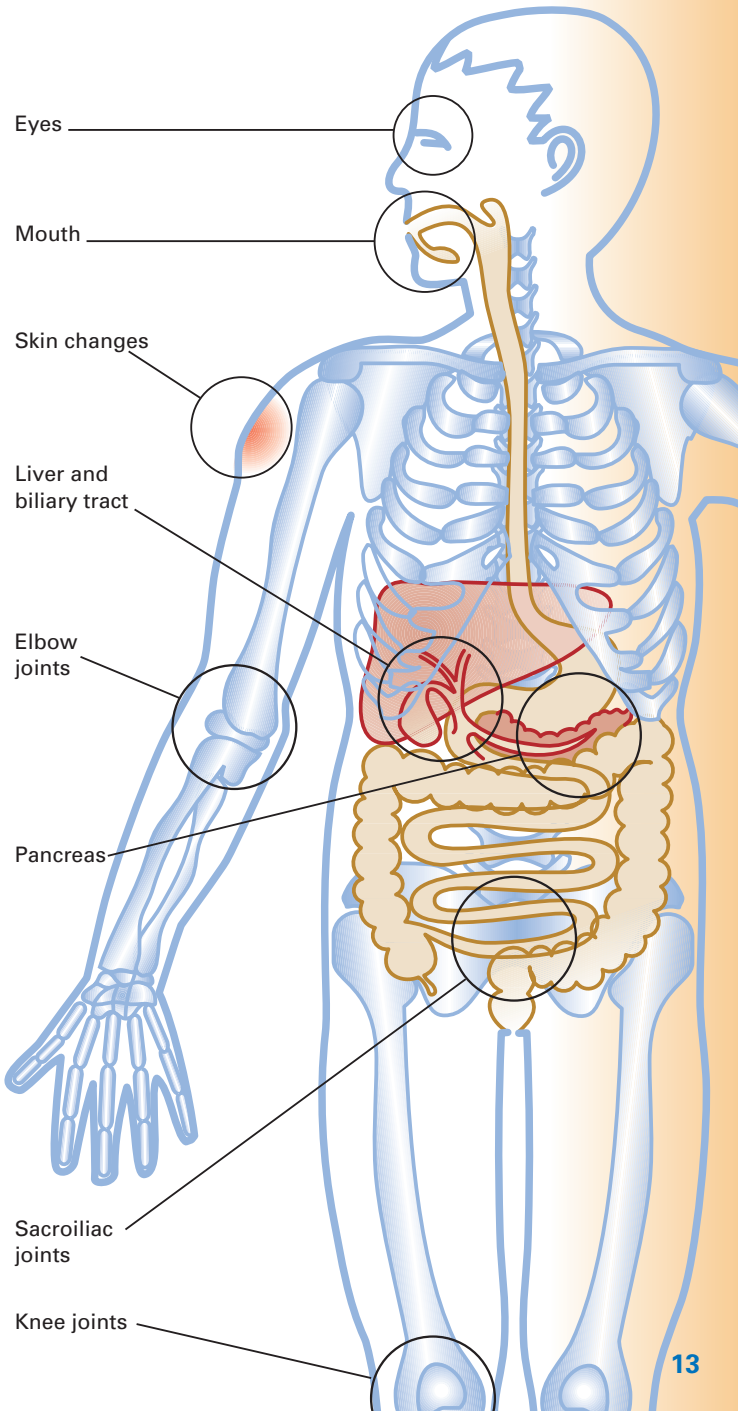
What are the symptoms of ulcerative colitis and Crohn's disease?

Both ulcerative colitis and Crohn's disease are characterized by an inflammation of the mucosal lining of the intestine. Thus, some symptoms are common to both diseases. However, there are fundamental differences due to the fact that the type, extent and location of the inflamed bowel segments differ between ulcerative colitis and Crohn's disease.

Although there are some **general signs of the disease**, such as reduced physical performance, fatigue, loss of appetite, and occasionally fever, the **main signs of the disease** are directly caused by the disease affecting the bowel. These include:

Bowel movement irregularities, ranging from bowel movements containing mucous or blood to severe **diarrhea**, and **abdominal pain** that sometimes radiates from a certain point and sometimes occurs across the entire abdomen, and that can be crampy or constant. **Nausea** and even vomiting is also not uncommon. The inflammation may also lead to a loss of blood through the bowel – often this blood is hidden in the stool and can only be detected using special test methods – and this in turn causes **anemia** to develop. Since iron is constantly lost along with the blood, the bone marrow lacks the iron necessary to form new blood cells. This condition is known as **iron deficiency anemia**.

*Involvement of other organs in the case of inflammatory >
bowel disease (= extraintestinal manifestations)*



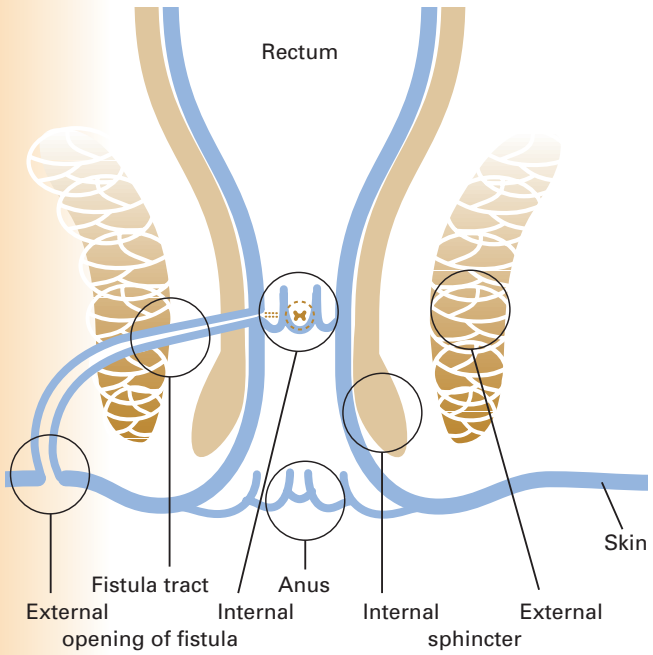
Both diseases can have **effects** on **other areas of the body**, apart from the bowel. This means that sometimes, inflammation may occur in the large and small joints of the arms and legs and in the **joints** of the spine and the pelvis. This joint inflammation results in joint swelling, pain, and impaired mobility. The **skin** can also react to intestinal inflammation. Such reactions may, for instance, take the form of painful areas of purplish-red thickened skin, usually occurring on the arms and legs (erythema nodosum), or they may take the form of deep ulcers (pyoderma gangrenosum).

A somewhat less common reaction is inflammation in the region of the **eyes**, especially in the iris and the conjunctiva. In both **ulcerative colitis** and **Crohn's disease**, uncharacteristic inflammation of the liver tissue may sometimes occur at the same time. In rare cases, the **bile ducts** can react with inflammation that causes scarring, thus leading to jaundice and digestive disorders (primary sclerosing cholangitis, PSC). Other very rare reactions include inflammation of the heart sac (pericardium) or of the pancreas, as well as venous thrombosis.

In **ulcerative colitis**, which only affects the large bowel, acute flare-ups are more typically characterized by blood/mucus in the stool. The severity of the **diarrhea** mostly depends on the inflammatory activity and the extent of the inflammation. Diarrhea is particularly severe in cases in which the entire large bowel is inflamed. However, if only the final portions of the large bowel (the sigmoid colon or rectum) are inflamed, as in ulcerative proctitis, the stool may be more solid, but traces of blood can still be detected.

Crohn's disease may affect both the small bowel and the large bowel. In its initial phase, it tends to cause only few symptoms and, particularly in cases in which the large bowel is only slightly inflamed or not inflamed at all, there may be no diarrhea. The most prominent symptom is typically **abdominal pain**, which can sometimes be confused with appendicitis. **Crohn's disease** is associated with nutritional deficiencies in its early stages, resulting in weight loss. It is not uncommon for the disease to manifest as **inflammation in the region of the anus**, leading to the formation of fistulae and abscesses. A fistula is an abnormal, "short circuit" connection that occurs either between two bowel segments, or between the bowel and the skin, or between the bowel and the bladder or vagina (see illustration on page 16).

In the case of weeping, purulent fistulae that occur repeatedly in the region of the anus, the bowel should always be examined further. Whenever a patient reports the occurrence of several of the above described symptoms, the physician will consider the possibility of IBD.



Perianal fistula in Crohn's disease (schematic illustration)

Methods of examination

What can the physician do to determine the type and extent of such a disease?

First of all, the physician will explain to you as the patient that **diagnostic procedures** now need to be carried out, which means that various examinations need to be performed.

The physician will begin with a **physical examination**, which means that they will check all over your body by feeling with their hands, listening, and tapping. They will focus on the abdomen and the rectum in particular. This examination will help the physician discover whether the skin, mucous membranes, eyes or joints show signs of disease. When examining the abdomen, it may be possible to determine the exact site of the pain, and the physician will be able to assess the condition of the liver and the activity of the bowel. When examining the anus, the physician will be able to recognize inflammation and, by gently examining the rectum with a finger, possibly find traces of blood.

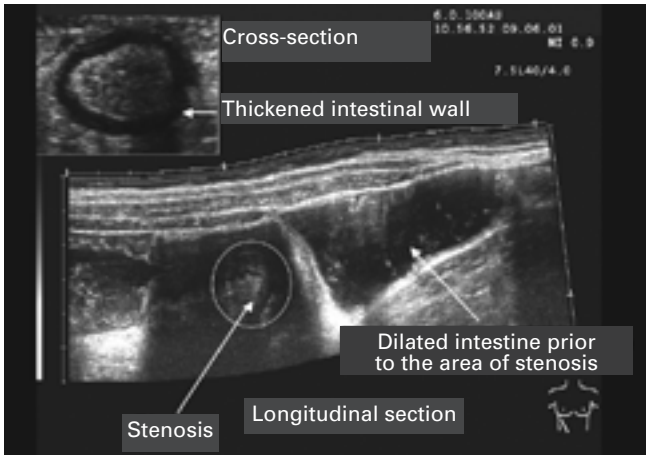
Afterwards, the physician will require blood and urine samples from you in order to perform **laboratory tests**. The erythrocyte sedimentation rate (ESR), the number of white and red blood cells and platelets (together known as the blood count), the protein composition of the blood (the result of the test called electrophoresis and the level of C-reactive protein [CRP]), as well as more specific laboratory values such as iron levels, vitamin levels (especially vitamin B₁₂ and folic acid) and levels of trace elements (especially zinc) all indicate whether there are general signs of inflammation, disturbances in nutrient uptake in the bowel, or hidden, chronic bleeding. The

urine tests enable the assessment of the kidneys and the urinary tract. Detection of **calprotectin**, an inflammatory marker found in the stool, indicates that intestinal inflammation is present. In the case of functional disorders without inflammation, levels of calprotectin are not elevated. Calprotectin is produced by inflammatory cells that migrate to the intestinal wall in the case of inflammatory bowel disease. The level of calprotectin indicates how severely the intestinal wall is inflamed. However, elevated levels are not only found in the case of inflammatory bowel disease, they are also found in the case of viral infections of the intestines, or in the case of acute bacterial diarrheal diseases.

If the results of these tests confirm the suspicion that inflammatory bowel disease is present, **further examination methods** will need to be used to determine the exact type of the disease, as well as its location in the gastrointestinal tract, i.e. its extent.

The least burdensome of all these methods is the **ultrasound examination of the abdomen**, also known as sonography. In most cases, ultrasound effectively detects changes such as widening of the bowel and thickening of its wall, changes in the liver, gallstones and kidney stones, abscesses, and problems with the flow of urine out of the kidneys. Ultrasound is completely harmless and can be safely repeated as often as necessary. Thus, any suspicious findings can be re-examined and monitored. Ultrasound is an excellent way to monitor Crohn's disease, and in many cases it can replace colonoscopy.

When determining the **type and extent** of inflammatory bowel disease, the location of the inflammation must be found. A number of methods can be used to do this, including **endoscopy** of the gastrointestinal tract and



Sonography: Longitudinal (lengthwise) slice through a section of the bowel that is ballooned with fluid held back by an area of narrowing (stenosis). In this slice, you see the stenosis as a thin, irregular black band (see arrow). This black band is actually what remains of the opening inside of the bowel. The cross-sectional slice shows that the intestinal wall is significantly thickened in the area of the stenosis (8–10 mm, compared with a normal wall thickness of 1.5–3 mm measured by ultrasound). (The images have been made available by Prof. Dr. K. Schlottmann, Innere Klinik I, Katharinen-Hospital Unna, Germany).

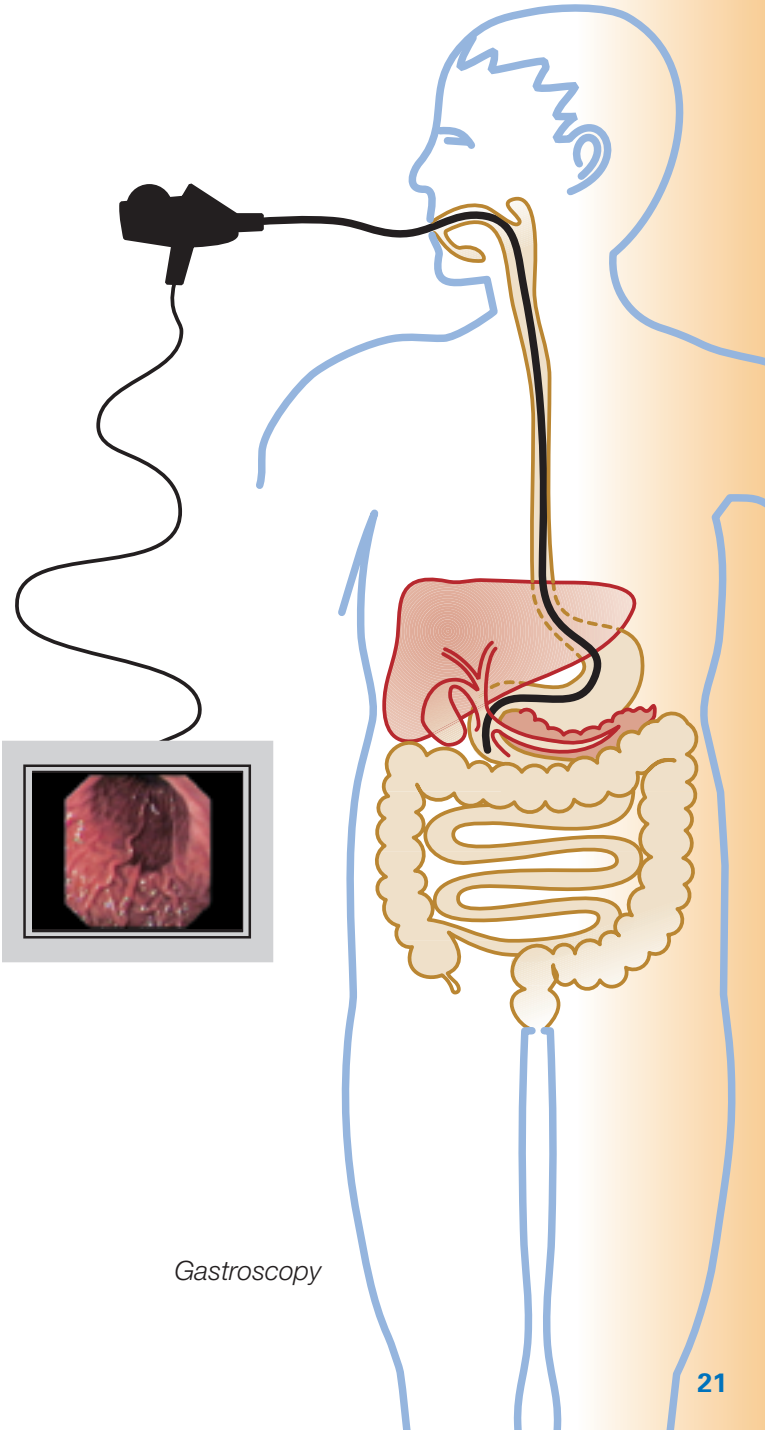
radiological examinations or “sectional imaging” techniques such as computed tomography (CT) or magnetic resonance imaging (MRI).

Endoscopic examination of the stomach (**gastroscopy**) can be used to depict the esophagus, the stomach, and the duodenum. A **colonoscopy** can be done via the anus/rectum in order to access all segments of the large bowel, and usually also the final few centimeters of the small bowel (known as the terminal ileum).

The procedure is performed with an endoscope, which is a flexible, tube-like instrument with a diameter of 9–12 mm. These high-precision instruments have a camera integrated into their tip and are connected to a monitor. The endoscope emits light into the stomach or the intestines, then a light sensor transmits the image to the external monitor. The endoscope also has a separate channel through which a thin instrument can be introduced for the purpose of taking tissue samples. This instrument is known as a biopsy forceps.

Endoscopy permits the examiner to look directly at the inner lining (mucous membrane) of the large bowel. In this way, normal lining tissue can usually be easily distinguished from sections of the lining that are inflamed. In addition, tissue samples can be taken from affected areas of the intestinal lining and examined using microscopic methods. This is known as **histology or histological examination**. This direct examination of samples of mucous membrane under the microscope makes it possible to determine whether inflammation is present, how severe it is, and what type of inflammation it is. Thus, it can be used to establish a diagnosis of IBD and can usually also be used to differentiate between **ulcerative colitis** and **Crohn's disease**.

In a **gastroscopy** (see illustration on page 21), the endoscope is introduced through the mouth and advanced through the esophagus into the stomach and duodenum. This examination must be done with the patient in a fasted state to prevent any food remaining in the stomach from interfering with the inspection of the mucous membrane (stomach lining). The examination is painless. However, you may feel an unpleasant pressure in your throat while the instrument is being inserted and some pressure in the region of your stomach. These discomforts can be greatly reduced with the help of suitable medication.



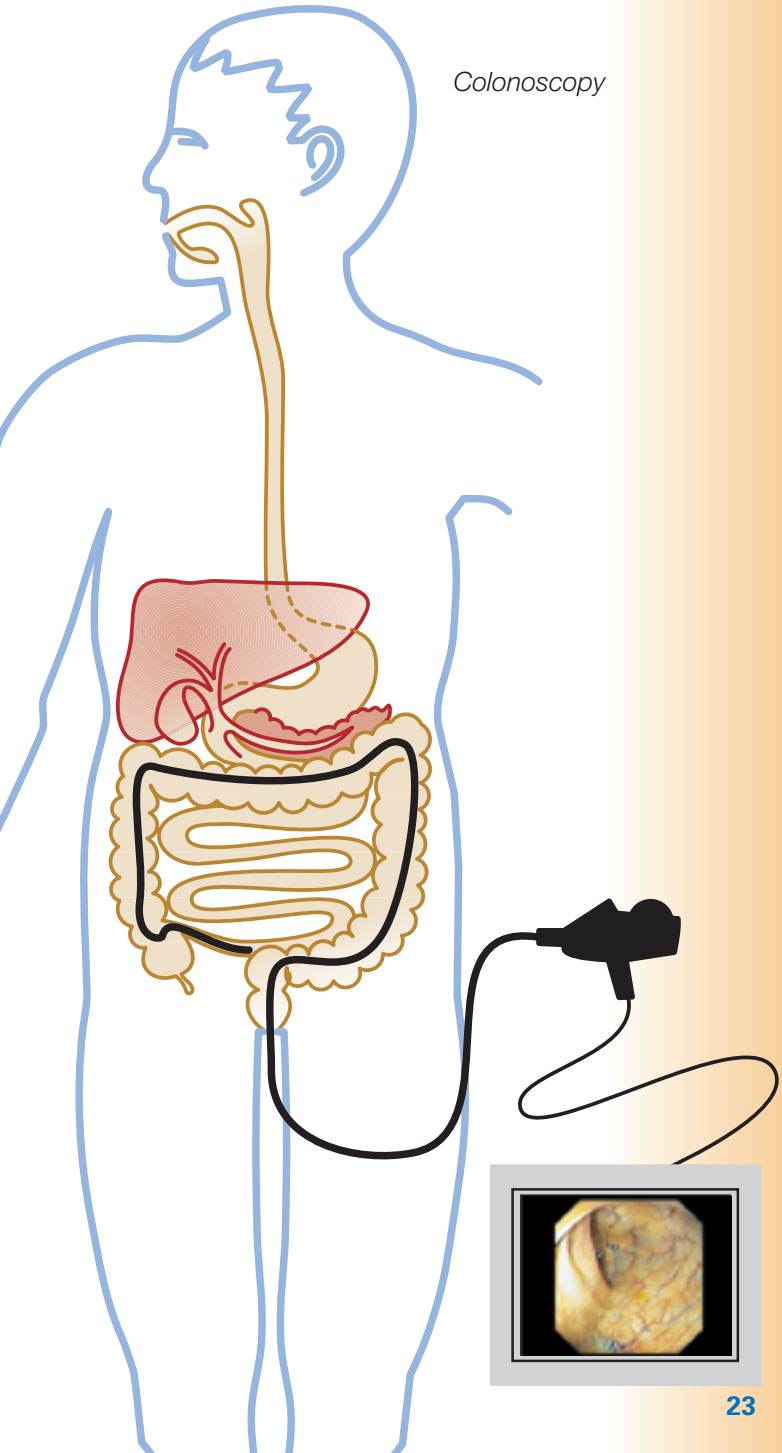
Gastroscopy

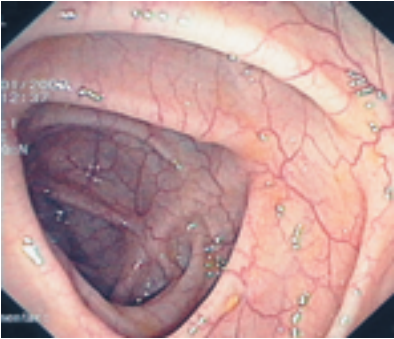
In a **colonoscopy** (see illustrations on pages 23 and 24), the endoscope is introduced through the anus and advanced up the rectum and through the entire length of the colon up to the entrance of the small bowel. Once the junction between the small bowel and colon (the ileocecal valve) is passed, the terminal portion of the small bowel can also be inspected. Colonoscopy requires more intensive preparation. Patients are not permitted to consume any solid food for 24 hours prior to the examination. On the day before the examination, the patient may eat breakfast. For lunch, however, only a soup or a light meal is allowed. In the afternoon and evening, the patient must also consume a suitable irrigating solution (about 3–4 liters) in order to cleanse the bowel. Various irrigating solutions are available with different tastes and volumes. After this, only mineral water or tea is allowed. In the 48 hours prior to the examination, you should not eat anything with seeds, such as kiwi fruit or tomatoes.

Colonoscopy can be painful, particularly if there are adhesions in the abdomen. However, patients can be given injections that help relax them and relieve pain, making the examination almost painless.

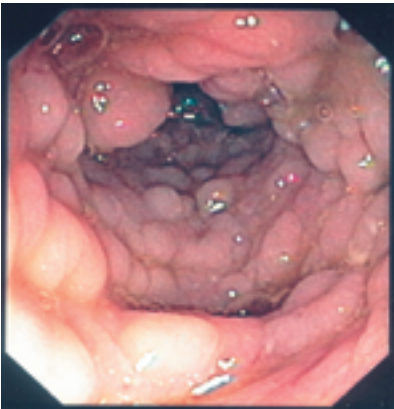
Proctoscopy is an endoscopy of the rectum, covering the last 5–10 cm above the anus. However, it is more common for patients to undergo **sigmoidoscopy**, a procedure that permits the inspection of the last 30–40 cm of the large bowel. Prior to both procedures, the bowel is cleansed with an enema. Then, the examiner inserts either a short, stiff tube (rectoscope) or a short, flexible endoscope (sigmoidoscope). Tissue samples can be taken as part of both of these examination procedures. Both of the above methods are suitable ways to assess inflammation in the rectal area, and both are also sufficient for follow-up purposes.

Colonoscopy

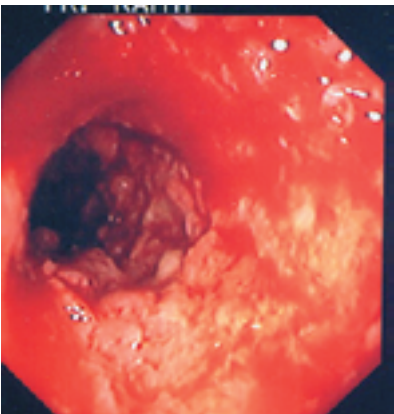




*Colon –
normal findings*



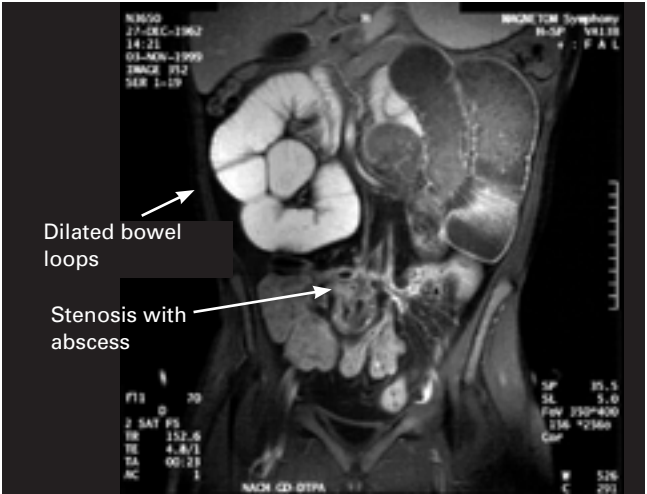
*Crohn's disease –
chronic inflammation
with pseudopolyps*



*Ulcerative colitis –
severe inflammation
of the mucosa*

Radiological examinations are another way to examine the gastrointestinal tract. In cases of inflammatory bowel disease, imaging of the small bowel is especially important. The procedure most commonly used for this purpose in Germany and Central Europe today is **magnetic resonance imaging (MRI)**. It is a good way to assess the small bowel without radiation exposure (see figure on page 26). This is particularly important for young patients with inflammatory bowel disease because the disease can cause problems over the course of many years, meaning that such examinations have to be performed again and again. It used to be necessary to pass a probe through the stomach into the small bowel in order to perform this procedure, but today this is no longer the case. MRI is also a very effective way of assessing findings outside of the intestines, such as fistulae or enlarged lymph nodes. In the case of an acute problem, or if an abscess is suspected, a **computed tomography (CT)** scan may be required. This examination can be performed more quickly and depicts abscesses more clearly, but it is somewhat less suited for assessment of the small bowel and it is associated with a certain level of radiation exposure. The amount of radiation you are exposed to in a CT scan is still not very high. Nevertheless, as the number of examinations performed increases, it can become a concern.

There are also two newer endoscopic techniques: **capsule endoscopy** and **double-balloon endoscopy**. Capsule endoscopy makes it possible to examine the small bowel in its entirety. Previously, this could only be done using radiological procedures. However, capsule endoscopy can only be used to view the intestines – it cannot be used to take tissue samples. This method is also not suitable for assessing the stomach. A special capsule camera has been developed for the assessment of the large bowel. For patients with Crohn's disease,



MRI-enteroclysis showing significant ballooning of the small bowel. There is a buildup of the contrast medium (pineapple juice) where it is blocked at the narrow point (the stenosis). An abscess has also formed at the stenosis.

capsule endoscopy is associated with a certain risk because although the endoscopy capsule is relatively small, it may get stuck in an area of the small bowel where there is narrowing (stenosis or stricture). In the worst case scenario, this can result in acute intestinal obstruction, requiring immediate surgery. Capsule endoscopy is most useful when Crohn's disease is suspected and all other available procedures have failed to yield conclusive results.

The second newer endoscopic procedure is **double balloon endoscopy**, which uses a specially designed endoscope to examine much longer sections of the small bowel than could be examined previously using conventional endoscopes. Unlike capsule endoscopy, double-balloon endoscopy can be used to obtain tissue

specimens from the small bowel, as well as to stop bleeding and remove polyps. In the future, this technique may potentially be used to dilate short narrowed areas of the small bowel (stenosis) that would have required surgery in the past. As with capsule endoscopy, this procedure is of limited benefit to patients with confirmed inflammatory bowel disease.

If you are now asking yourself whether all of these examinations must be performed, you can relax. More extensive examinations are normally required only to confirm the initial diagnosis of a disease and to determine its extent.

The examination methods applied vary from person to person, and depend above all on how the condition manifests in an individual patient. Radiological methods and endoscopy can be used to complement each other here. Usually, endoscopy is used to examine the more easily accessible segments of the digestive tract because it avoids the need for radiation exposure, and if there are any suspicious findings, these can be investigated by taking tissue samples immediately for microscopic evaluation. In order to properly evaluate the small bowel, as well as in cases in which the presence of fistulae or severe narrowing (stenosis) in the colon are suspected, it will not be possible to avoid having MRI or CT scans. Detailed analysis of fistulae and/or abscesses in the rectum is often performed by means of an ultrasound examination of the rectum (**endosonography**) or by means of MRI.

In an endosonography, an ultrasound transducer head is introduced through the rectum. This permits examination of the tissue and any fistulae that may be present.

What must be done to monitor the course of inflammatory bowel disease?

Both **ulcerative colitis** and **Crohn's disease** are chronic diseases of the bowel that can become inactive and may remain in the inactive state, but long-term medical monitoring is required. This means regular visits to the physician: at least twice a year is recommended, even if you are free of symptoms. Regardless of any medication treatment, the course of the diseases will be better if regular follow-up examinations are performed. This has been clearly demonstrated in scientific studies. If you need **long-term medication, follow-up examinations** must be performed at least every three months, or perhaps even more often (depending on the drug). In addition to the clinical examination, which includes the examination of the abdomen and the bowel by feeling with the hands, blood tests are another important examination method. These tests help identify signs of inflammation or nutritional deficiencies. At least once a year, your physician will order an ultrasound examination of the abdomen. If there is no evidence of inflammation, the more burdensome examination methods can usually be avoided.

During an acute disease episode or flare-up, patients do not necessarily have to undergo the entire battery of tests again. Only in cases in which symptoms have changed significantly compared to earlier flare-ups is it helpful to re-assess the extent of the disease, since in the course of the disease, changes may occur that could possibly necessitate a modification in treatment strategy. In the case of **ulcerative colitis**, this applies if the disease did not initially involve the entire colon. In the case of **Crohn's disease**, both the small and large bowel must sometimes be examined in order to check for complications such as fistulae or stenosis. If there

are no changes in the symptoms and the disease remains inactive, no further follow-up examinations are necessary. Only patients who have suffered from ulcerative colitis for a long period of time (more than 10 years) should undergo regular colonoscopy (ideally once a year) in order to detect any tumors promptly. This is particularly important in extensive and chronically active colitis.

In the case of ulcerative colitis, sigmoidoscopy is useful as a way of accurately assessing whether medication treatment has been successful and whether the mucous membrane has healed. In the case of Crohn's disease, follow-up endoscopic examinations are required 6–12 months after surgery in order to ensure that the medication to prevent relapse is working adequately.

Causes

What causes inflammatory bowel disease?

The actual cause of inflammatory bowel disease remains elusive. However, in the last few years, we have gained important knowledge that has transformed our understanding of inflammatory bowel disease.

It is likely that these chronically recurring episodes of inflammation in the bowel are caused by a complex interaction between various environmental factors and a hereditary predisposition for these diseases. We are now aware of more than 200 human genes that are responsible for a predisposition to Crohn's disease or ulcerative colitis. To date, changes in numerous genes have been discovered that play a greater or lesser role in the development of Crohn's disease. The most important of these genetic changes in patients with Crohn's disease discovered so far was identified by scientists in 2001. They showed that changes (mutations) in a gene known as the NOD2 gene significantly increase the risk of developing Crohn's disease. These changes appear to be at least partially responsible for the occurrence of the disease in about 30% of all Crohn's patients. However, it is clear that such a hereditary predisposition alone is not enough to trigger the manifestation of the disease. This is why even though up to 10% of healthy people in Central Europe also have mutations in the NOD2 gene, they never develop Crohn's disease. This means that in addition to genetic predisposition, other, environmental factors that have yet to be definitively identified are required in order for an individual to actually develop the disease. These factors may include infections with viruses or bacteria, changes in nutritional behavior or the consumption of certain food additives, or disorders

of the body's own immune defense system or of the intestinal barrier. To date, no definitive evidence has been found to prove a connection between these factors and the development of inflammatory bowel disease. It is, however, very probable that environmental factors play a role because these diseases are much more common in developed countries than in other regions of the world. That being said, these diseases are becoming markedly more common in the emerging economies as lifestyles in these countries become more like those in developed countries. Inflammatory bowel disease is not infectious; there is no need to fear catching it from someone who has it.

Psychological burdens and stress can trigger a flare-up of an existing disease, but they are not the cause of inflammatory bowel disease by themselves.

It is also still not known what causes the **inflammatory changes in other organs**, such as the joints, the skin, or the eyes. One explanation may be an overreaction on the part of the body's immune defenses, but this has not been proven.

On the other hand, the reasons why many of the **sequelae** (associated conditions) of inflammatory bowel disease occur are well known. For example, the reduced absorption of vitamins and some trace elements (minerals) in patients with IBD is often responsible for symptoms such as night blindness, hearing disorders, changes in the sense of taste, increased susceptibility to infection, hair loss, infertility (in men), growth disorders (in children) and certain skin changes. Anemia may be caused by iron deficiency, by loss of blood from the bowel, or by vitamin B₁₂ malabsorption. A reduced uptake of bile acids in the small bowel and an increased uptake of bilirubin is responsible for the increased fre-

Hair loss

Impaired vision

Hearing disorders

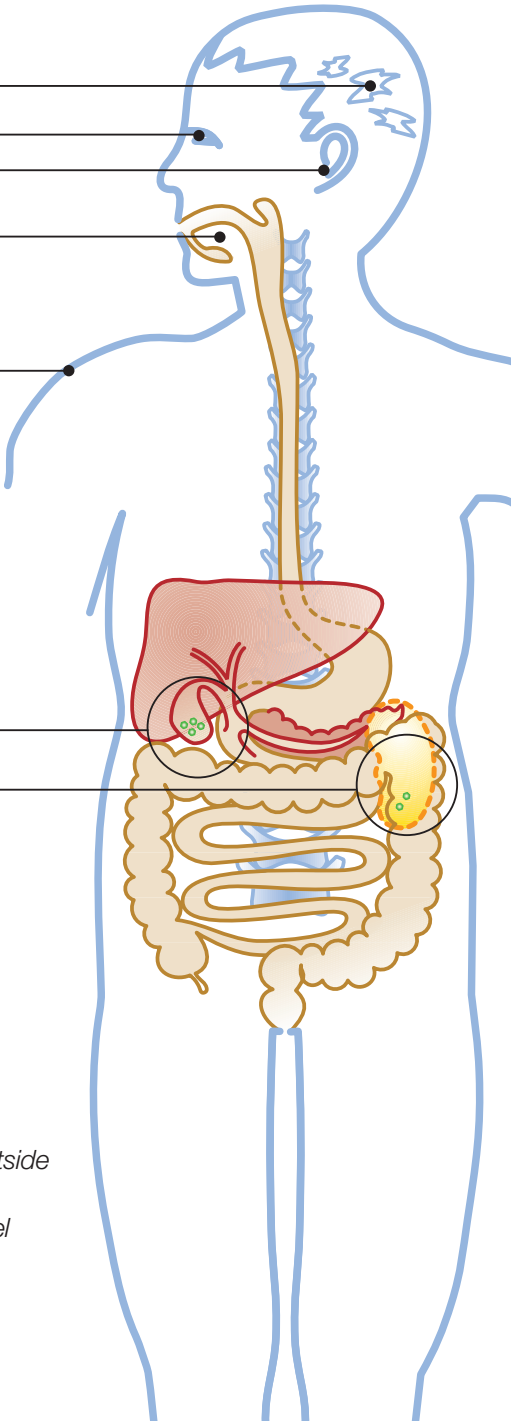
Loss of sense
of taste

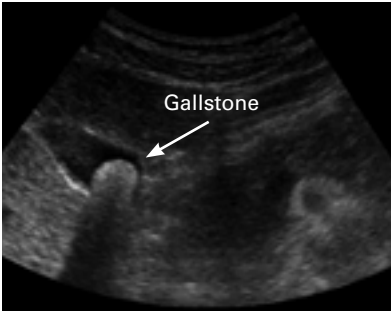Skin changes

Gallstones

Kidney stones

*Complications outside
of the bowel due
to disturbed bowel
function in IBD*





Gallstone in the gallbladder of a patient with Crohn's disease (ultrasound image)

quency of gallstones. Causes of kidney stones include the loss of water from the intestines and increased absorption of oxalate in the gut.

In either of the main types of IBD, serious **complications** such as acute ballooning of the bowel ("toxic megacolon") or the formation of a hole in the wall of the bowel (perforation), may occur in very rare cases. Peritonitis, the inflammation of the membranous lining of the abdomen, and intestinal obstruction or paralysis (ileus) may result. These are life-threatening conditions requiring immediate hospital admission and usually emergency surgery. Severe intestinal bleeding is unusual in patients with ulcerative colitis. Narrowing of the bowel caused by inflammation or scar tissue formation (stenosis) and fistulae between the bowel loops and other organs are among the consequences of Crohn's disease.

Treatment

Both, ulcerative colitis and Crohn's disease are chronic diseases. This means that the patient will continue to have them for the rest of his or her life. The progression of the disease, however, can differ significantly from patient to patient. While some individuals have a very mild disease with infrequent flare-ups, in others, the disease takes a much more severe course with frequent flare-ups and frequent hospitalizations. Unfortunately, it is currently impossible to predict the future disease course of an individual patient with a new diagnosis of IBD. However, studies have shown that a large proportion of patients with ulcerative colitis or Crohn's disease tend to exhibit a mild clinical course, and a third of those affected do not require even one course of treatment with cortisone preparations.

What treatment methods are available?

Treatment options fall into four main groups and include drugs, surgery, diet and supportive measures. **One very important supportive measure is for the patient affected with Crohn's disease to quit smoking.** Compared to smokers, patients who quit smoking are 60% less likely to have another disease flare-up within a two-year period.

The treatment of ulcerative colitis

The primary goal of treatment is to improve patients' symptoms (diarrhea, pain, blood loss) and, once this is successful, to prevent relapse (another flare-up).

In order to do this, the changes in the mucosa must be healed as completely as possible. Today, there is a wide range of different medications available to achieve these aims. The treatment chosen depends on the extent of the inflammation and the severity of the symptoms.

5-aminosalicylic acid is used in the case of mild to moderately severe inflammatory episodes. If the joints are also affected, **sulfasalazine** can also be used. This drug, discovered in 1942 by the Swedish physician Nanna Svartz, was the standard treatment for ulcerative colitis prior to the introduction of 5-aminosalicylic acid.

5-aminosalicylic acid (also known as **mesalazine**), is typically given in pharmaceutical preparations that allow for release in starting in the lower third of the small bowel, and continue to release the drug throughout the large bowel. It then directly treats the inflamed mucosa in these areas. These preparations can be taken once a day as a single dose.



Dr. Nanna Svartz

Particularly with the most common forms of ulcerative colitis in which the disease affects only the rectum or the left side of the colon (80% of patients), rectal treatment with suppositories, enemas or foams that contain **5-aminosalicylic acid** has proven effective. However, the use of enemas and foams in addition to tablets or granules is also helpful in the case of extensive colitis.

If this treatment is not sufficient, enemas and foams containing **cortisone** or **cortisone derivatives (budesonide)** can be used. Budesonide has far fewer side effects than classical cortisone preparations.

In severe cases of the disease, the administration of **cortisone preparations** either as tablets or injections is usually effective. If this is not the case, medications that more strongly reduce the body's immune response will be used.

For patients who respond to cortisone preparations, but then experience symptoms again following dose reduction, **azathioprine** or its metabolite (breakdown product) **6-mercaptopurine** can be used.

However, these two substances often only reach their full effect after 12 weeks of treatment, and only about 60% of patients respond to this treatment. About 10 in 100 patients experience more serious side effects, namely hepatitis, acute pancreatitis, or disorders of blood cell formation. Therefore, after starting treatment, patients must initially undergo laboratory tests every two weeks (blood count, liver function test, and pancreatic function test). If the test results are normal, then starting from the third month, the frequency of the tests can be reduced to every two months.

If this treatment is successful (i.e. if it is possible to stop using cortisone preparations permanently without the recurrence of flare-ups), then these medications should be taken at least for two to four years.

In the case of a very severe flare-up where cortisone treatment does not result in rapid improvement, treatment in hospital is required. In such cases, **cyclosporine** can be administered as an intravenous infusion over the course of 24 hours for 7 to 14 days. Alternatively, antibodies against the inflammation-promoting transmitter substance tumor necrosis factor- α (TNF- α), such as **infliximab**, **adalimumab**, or **golimumab**, can be used. They are about as effective as cyclosporine. If these treatments do not bring any improvement, the large bowel must be surgically removed (**colectomy**, see below).

Anti-TNF- α antibodies are also required in the case of patients who still have frequent flare-ups or chronic disease activity despite the treatments mentioned above. Alternatively, a drug called **vedolizumab**, which blocks the migration of inflammatory cells into the tissues of the intestines, can be used. If this substance works, the effect often lasts for a longer period of time.

If a **symptom-free state** (remission) is achieved, long-term treatment is still required, and the treatment chosen depends on exactly how remission was achieved. 5-aminosalicylic acid is often used. Patients who were successfully treated with cyclosporine are given azathioprine in order to maintain the effect. In the case of treatment success with **anti-TNF- α** , treatment is continued; the same applies to treatment with **vedolizumab**.

Like all drugs, the drugs mentioned here can cause **side effects**. With drugs that suppress the immune

system in particular, it is especially important to watch out for infections. In rare cases, malignant tumors may occur, particularly on the skin.

The detailed description of these side effects on the package insert should not cause you to avoid or stop taking the drug out of fear. Instead, you should always consult your physician, who will use appropriate methods to determine whether, in your case, the administration of the drug should be stopped or the dosage changed. Complications are more frequently caused by patients discontinuing their medication without consulting their physician than by side effects of the drugs themselves. This is also true for patients whose disease is currently inactive.

Older studies have shown that the administration of specific **probiotics** (substances that influence the bowel's bacterial flora, such as *Escherichia coli* Nissle and various lactobacilli) is just as effective in preventing disease relapse as 5-aminosalicylic acid. This method may be particularly suitable for patients who do not tolerate 5-aminosalicylic acid. However, the efficacy of this method in the treatment of Crohn's disease or in the treatment of the acute disease phase of ulcerative colitis has not been proven.

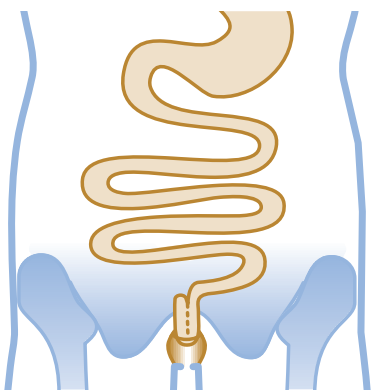
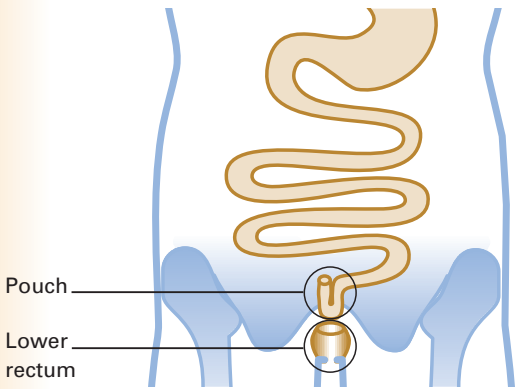
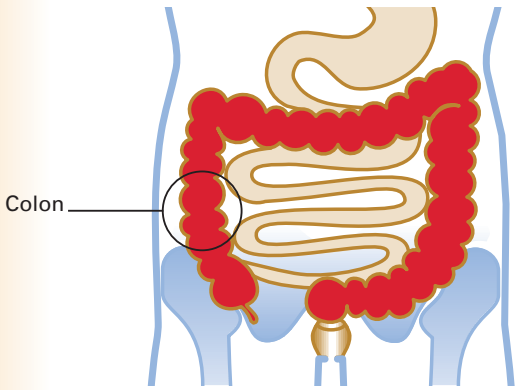
In addition to the testing of new drugs, new and interesting treatment concepts are currently being investigated in clinical studies. These new treatment concepts include inhibiting various mediators of inflammation, or strengthening the intestinal barrier. As with all new therapeutic methods, studies must be conducted to comprehensively investigate both their effects (in this case whether or not the treatment is successful) and their possible side effects.

Because drug treatment has a high success rate, surgery is rarely necessary. Life-threatening complications (see page 33), severe symptoms that persist despite adequate treatment, and serious drug-induced side effects are all indications for surgery.

In the case of ulcerative colitis, the **removal of the entire colon** cures the disease. In many cases, it is possible to remove the colon without the need to create a permanent artificial bowel outlet. This involves surgical creation of a “pouch” out of loops of small bowel that act as a reservoir and as a substitute for the rectum (see illustration on page 40). In most cases, this results in almost normal stool consistency and a bowel movement frequency of about five to eight times per day.

Patients with ulcerative colitis do not require a **special diet**. It is advisable, however, to avoid foods such as cabbage, onions, or fatty foods that may cause symptoms even in healthy persons. In our experience, it is usually best for each patient to test out his or her own individual tolerance to different foods. Deficiency symptoms occur only very rarely in patients with ulcerative colitis. When they do occur, they may manifest themselves as edema (retention of water in the tissues due to protein deficiency) or anemia (due to blood loss or iron deficiency) occurring most often in instances of prolonged disease flare-ups. These deficiencies can be treated by supplementing the appropriate substances.

The **manifestations of the disease that occur outside of the bowel** (in the joints, skin, eyes) can usually be successfully treated with drugs (usually with agents that contain cortisone). Surgical or dietary measures are not very effective. Changes occurring in the biliary tract are treated with ursodeoxycholic acid, a bile acid. Ursodeoxycholic acid cannot reverse these changes, but it



can slow their progression. Every case of abnormal liver function test values must be thoroughly investigated and treated accordingly.

The treatment of Crohn's disease

The treatment of Crohn's disease is based on the same principles as the treatment of ulcerative colitis. However, because of the more divergent patterns of disease, symptoms and complications, it is more challenging to find the **optimum treatment** for each individual patient.

Because Crohn's disease affects the entire intestinal wall and not only the mucosa, it is unclear whether endoscopically observed complete **healing of the inflammation** ("mucosal healing") is as important a treatment aim as it is with ulcerative colitis, or whether a symptom-free state is a sufficient aim.

An acute flare-up of Crohn's disease is usually treated with **cortisone preparations**. Particularly in patients who have inflammation in the region of the connecting segment between the small and large bowel (ileocecum), **budesonide** is used. Budesonide works about as well as the classical cortisone preparations, but has far fewer side effects because after it delivers the intended effect in the bowel, it is broken down in the liver, and only a small portion of it reaches the rest of the body.

◁ *During the surgery in which the pouch is created, the whole colon is removed with the exception of a small section of the lower rectum. A pouch is then created out of a part of the small bowel (terminal ileum) and sutured to the remaining portion of the rectum.*

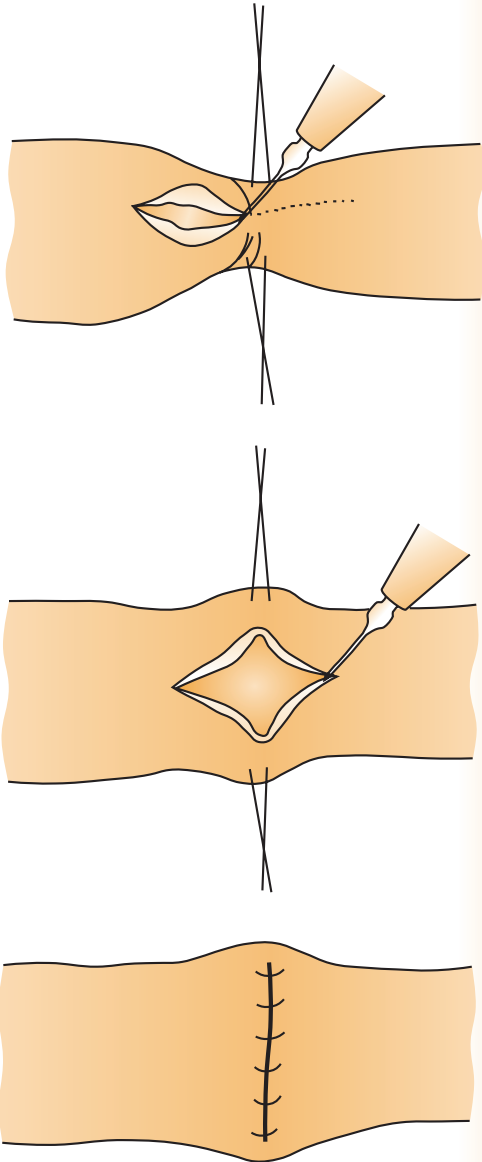
In addition, **5-aminosalicylic acid preparations (mesalazine)** are used in patients who have a mild flare-up, or who are known to have a milder disease course.

If these treatment options are not enough, drugs that more strongly suppress the immune system are used. These include **azathioprine/6-mercaptopurine**, anti-TNF- α antibodies, **vedolizumab**, or the new drug **ustekinumab**, an antibody against the inflammation-promoting transmitter substances interleukin-12/interleukin-23.

As described above for ulcerative colitis, all of these substances also have **side effects** that patients need to watch out for (e.g. more frequent “colds”, fever, anemia). If you have any of these symptoms, or any other symptoms that you are not sure about, it is crucial that you ask your doctor about them, but you should never stop taking your medication or change your dosage on your own.

After surgery, the use of **5-aminosalicylic acid preparations** can reduce the frequency of relapse to a certain extent. Depending on the results of the follow-up endoscopy, stronger drugs such as azathioprine or anti-TNF- α preparations may be used.

If the aforementioned drug-based treatments are not successful, or if complications such as intestinal obstruction or stenosis occur, a **surgical procedure** will be necessary. In such a procedure, the transition area between the ileum and the colon is often removed (see figure on page 45). When surgery is recommended, emphasis is placed on techniques that preserve as much bowel as possible. Short areas of narrowing (stenoses or strictures) can be dealt with using a technique called stricturoplasty (see figure on page 43). This surgical



The stricturoplasty technique. A longitudinal (lengthwise) incision is made in the area of stenosis and then the bowel is closed in a cross-wise fashion.

procedure involves making a longitudinal (lengthwise) incision in the area of stenosis and then closing the bowel wall in a cross-wise fashion. This widens the narrowed part of the bowel, making the normal passage of stools possible again. The main advantage of this method is that no bowel must be sacrificed.

Surgery can also be considered for the treatment of fistulae. Abscesses are sometimes treated by means of a **drain** placed through the skin (guided by ultrasound or computed tomography). However, after the symptoms have subsided, surgery is usually required to treat the underlying cause, which may be a fistula or a narrowing of the bowel. Even after successful surgery, regular follow-up by experienced internists and surgeons working together is still required so that any complications that may arise are detected quickly.

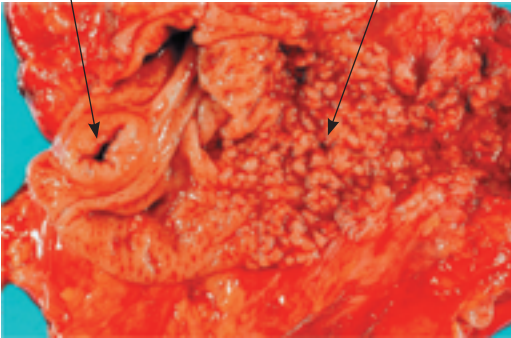
Unlike **ulcerative colitis**, **Crohn's disease** can cause an array of **deficiency symptoms**. There may be deficiencies in vitamins, trace elements, minerals, or proteins. In such cases, it is important to use appropriate supplements, such as vitamins, calcium, iron, potassium, or zinc supplements (substitution). Your doctor will use regular blood tests to identify the exact nutrients that require substitution. Particularly after the removal of the final section of the small bowel, uptake of **vitamin B₁₂** may be impaired. In order to prevent the risk of a vitamin B₁₂ deficiency and the resulting anemia, life-long administration of this vitamin is usually required in the form of injections every 3 months.

As with ulcerative colitis, it is up to the patient to test out which foods work for them and which do not. That being said, it is always sensible to have a balanced diet that provides all of the nutrients, vitamins and minerals that you need.

Ileocecal valve

(the connecting segment between the small and large bowel)

Pseudopolyps



Surgical specimen after ileocecal resection: severe inflammatory changes in the colon with pseudopolyps

To date, no special diet has been discovered that can reliably speed up treatment or prevent relapse.

Psychotherapy

Opinions differ regarding the need for **psychotherapy** and its potential for success. What is certain is that inflammatory bowel disease cannot be cured with psychotherapy. Whether such therapy can help prevent an acute flare-up in patients with a high level of psychological stress is not known. However, behavioral therapy that helps patients cope better with their problems is likely to be beneficial. In any case, this kind of treatment should only take place in cooperation with your treating physician.

Special problems

What kinds of special problems may occur?

Now that we have discussed the issues of the development, diagnosis, treatment and follow-up of inflammatory bowel disease, we will turn to a few special problems that must be confronted by patients living with these diseases.

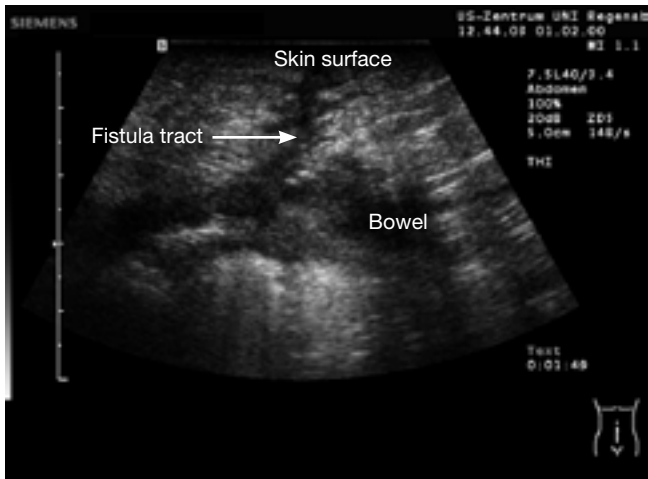
Course of the disease

Probably the most important question you will wish to discuss with your physician concerns the future course of your disease: How will it progress and what problems will you face in the future? As your doctor will tell you, in the case of inflammatory bowel disease, the **prognosis** (i.e. the probable future course of your disease) for each individual case can often only be determined after a long period of observation. We know today that the life expectancies of patients with ulcerative colitis or Crohn's disease are barely affected or are not affected at all, provided the patients are correctly diagnosed and appropriately treated. Both ulcerative colitis and Crohn's disease are **chronic diseases** that may affect your life for years to come. Both diseases tend to be **relapsing-remitting** in character. This means that they alternate between inactive phases, and phases of disease activity. Early, targeted treatment can usually suppress the inflammatory activity and lead to re-establishment of an inactive disease phase. Complications are more likely in patients in whom the inflammation has become chronic, causing the changes in the bowel to progress. What this means for you personally is that you will need **regular medical follow-up examinations** so that the inflamma-

tory phases of your disease can be caught early. In this way, the risk of complications is reduced as far as possible through targeted treatment. Flare-ups and associated complications can severely reduce your quality of life and overall happiness. Thus, the milder side effects of special long-term drug therapy can be tolerated with this larger goal in mind.

Fistulae

About one-third of all patients with Crohn's disease develop fistulae. Fistulae are a kind of "short circuit" connection between individual bowel loops, or between the bowel and other organs (such as the bladder or the skin). Fistulae most commonly form in the region of the anus. In this area, the fistula forms a connection between the rectum and the skin surrounding the anus



Ultrasound image: Fistula between a section of the bowel and the skin

(see diagram on page 16). The development of fistulae may be associated with complications such as the formation of abscesses (encapsulated accumulations of pus). Therefore, if new fistulae form, appropriate diagnostics will need to be carried out. These may include radiological examinations such as CT or MRI, **proctoscopy** and/or endosonography. The methods chosen will depend on the location of the fistulae. The treatment of the fistulae depends on their location and the associated complications. Often, treatment begins with antibiotics due to the associated inflammatory reaction. In certain cases, however, it may be necessary to surgically remove the fistulae or the bowel segment from which the fistula originates – especially in cases of fistulae that form between two bowel loops or in the case of abscess formation. In the long term, most patients will require either surgical treatment or drug treatment to close the fistulae. Antibodies that block the transmitter substance called tumor necrosis factor (= TNF) in the body and may lead to a (usually temporary) closure of the fistulae can also be successful. Newer procedures such as the injection of stem cells still need to be tested.

Osteoporosis

Over half of all patients with inflammatory bowel disease suffer from reduced bone density. A distinction must be made between mild and severe bone loss. However, both forms respond to drug treatment. Especially in the case of long-term administration of cortisone preparations, it is advisable to have bone density measured (the possibility of reduced bone density is one reason why long-term cortisone therapy should be avoided). This is done using radiological methods that expose the patient to relatively low doses of radiation. Treatment for mild forms

of bone loss consists of the administration of vitamin D. More severe bone loss may require the use of drugs called bisphosphonates, which directly inhibit bone loss.

The risk of cancer

As an informed patient, you may be aware that any chronic inflammation that lasts for a long period of time may be associated with the development of tumors. So what does this mean for patients with ulcerative colitis or Crohn's disease?

In the case of **ulcerative colitis**, we know that there is an increased risk of cancer in patients in whom the entire colon is affected and in whom the disease starts early, involves chronic activity, and has persisted for more than 10 years. For this reason, in patients who have suffered from **ulcerative colitis** for 10 years, **regular follow-up endoscopy** of the large bowel must be carried out at intervals of no more than two years. This is the only way to promptly detect the early signs of malignant degeneration, such as mucosal dysplasia. In such cases, surgery can prevent the development of cancer. The risk of cancer is significantly lower in the case of Crohn's disease. However, when only the colon is affected, as with ulcerative colitis, screening examinations should be performed once the disease has persisted for more than 10 years.

Psychological burden

The knowledge that you have a chronic disease, and the problems associated with the disease naturally affect your personal sense of intactness and your mental well-being in a very profound way. What can you do in order to better cope with these problems?

Rule number one: You must come to terms with your disease and accept it. You have the advantage of knowing about your disease, an advantage that many other people do not have. Coping with such a disease has meaning and finding you are able to cope can be a source of enhanced self-worth.

Rule number two: You must not let your illness control you. Those who lose hope suffer the most from their disease. You must actively confront your disease and live a normal life – despite, and even because of your disease. All means of actively confronting your disease are open to you. Even trying **alternative medicine** is better than giving up and doing nothing (but consult your doctor about this in order to avoid any unintended effects). The disease affects the individual as a whole. All therapeutic measures must therefore also treat the person as a whole.

Self-help groups

Coping with a long-lasting illness can often be made much easier by talking about it with others suffering from the same illness. This is why self-help groups and associations have been formed in many places.

Ability to work and professional life

During the active disease phase, you will not be able to work. This applies to inflammatory bowel disease just as it does to any other human disease, and it also applies to any kind of profession. Due to the relapsing-remitting and chronic course of the disease, short periods where you are unable to work due to illness are of course to be expected no matter what your profession. However, re-training in order to take up a different profession or giving up work is only necessary in rare cases. That being said, strenuous physical activity is not advisable in certain circumstances, such as after major abdominal surgery, or for patients who have fistulae, or whose disease cannot be sufficiently controlled with drugs. Nevertheless, you can certainly work in other professions that mainly involve sedentary activities or only light physical work.

Adolescents in particular (a group that has been more frequently diagnosed with inflammatory bowel disease in recent years) should aim to **complete their professional training**.

Leisure

The same applies to leisure as to work: Everything is open to you even though you have inflammatory bowel disease. Only in phases of severe inflammatory activity will your physical capacity be somewhat limited.

Exercise in all its forms is absolutely encouraged.

Travel abroad is also perfectly possible. Any vaccinations that you may need prior to travel, however, should

only be given after consultation with your treating doctor. This is because some vaccinations cannot be given or are not advised when using immunosuppressants.

Sex and partnership

Here, too, no specific restrictions are necessary. Sexual activity will naturally be reduced during an acute disease flare-up. In women, the body's natural mechanism for conserving energy and resources may result in interruption of menstruation.

In patients with **Crohn's disease**, fistulae may form in the genital and perineal area, thus affecting your sex life. Such fistulae require intensive medical attention and drug therapy. Therefore, it is recommended that you consult a specialist or a specialist center as soon as possible.

Reproduction and genetic factors

In our discussion of the causes of inflammatory bowel disease, we noted that genetic predisposition plays a role in both **ulcerative colitis** and **Crohn's disease**. Should this be considered a reason not to have children?

The probability of inheriting a predisposition to inflammatory bowel disease is low. Therefore, the risk that parents with the disease will have children who will also develop **ulcerative colitis** or **Crohn's disease** should likewise be considered low. This small risk should not deter persons affected by IBD from having children.

Pregnancy

This section is closely related to the last. Is it advisable for women with IBD to become pregnant and should these women attempt to carry pregnancies to term and deliver normally?

In answering these questions, it is important to state at the outset that pregnancy has not been shown to adversely affect the clinical course of either ulcerative colitis or Crohn's disease in any way. Therefore, if you **want to have children**, this is certainly an option. It is, of course, important to plan the pregnancy, so that it does not occur during a period of more pronounced disease activity. During the pregnancy, the patient should be **monitored** by an internist and a gynecologist working together. Should an acute disease flare-up occur during pregnancy, treatment with cortisone or 5-aminosalicylic acid preparations is possible. Targeted use of these drugs can treat the disease even during pregnancy without producing side effects in the embryo.

If long-term treatment with azathioprine is required, **contraception** should be used. However, if pregnancy occurs despite the use of contraception, the treatment should be continued. With the exception of the last trimester of pregnancy, this also applies to anti-TNF- α preparations due to the long half-life. Experience with vedolizumab and ustekinumab is not sufficient to make any statements in this regard.

The two most effective methods of birth control, namely hormonal contraception and the intrauterine device (IUD), are both somewhat problematic in patients with IBD. The forms of contraception that can be considered must be decided on an individual basis in a consultation with an internist and gynecologist.

The artificial bowel outlet

Newly developed surgical techniques make it possible in many cases of ulcerative colitis to remove the entire large bowel without creating a permanent artificial bowel outlet (see illustration on page 40). In fact, a permanent artificial bowel outlet (ostomy) is required only in very rare cases. The creation of a temporary ostomy in patients with ulcerative colitis or Crohn's disease may, however, have a beneficial effect on the disease. The temporary ostomy is usually closed after four to six months. Modern ostomy systems make it possible to live an almost completely normal life, including exercise and normal sexual activity, despite the artificial bowel outlet. Early retirement due to a permanent ostomy is necessary only in the rarest of cases.

If, however, you do require an artificial bowel outlet, you should contact others who have been in your position to hear about their experiences. Patients who have an artificial bowel outlet (ostomy patients) have formed self-help groups in many cities and countries.

What do IBD patients need to bear in mind?

1. Never forget: The more you control your disease, the less your disease will control you.
2. Keep going to regular medical follow-ups, even in phases when you have no symptoms. If you have complications, you should seek referral to a gastroenterology center as soon as possible, where there will be internists and surgeons who will work together to deal with your illness.
3. If you need to take medication on a regular basis for a long time, you must comply with this treatment as closely as possible. Medications should never be discontinued and doses should never be changed without first consulting with the treating physician. Ask your doctor about the possible side effects of your medication.
4. Keep an eye out for signs of disease activity. For **ulcerative colitis**, the signs are: changes in the stool up to and including bloody diarrhea accompanied by abdominal pain and general signs such as tiredness and reduced physical performance. For **Crohn's disease**, the signs are: abdominal pain, weight loss, changes in stool consistency (diarrhea or constipation), and a general reduction in physical performance. In both diseases, there may be symptoms that occur outside the bowel. These include: joint pain, inflammation of the eyes, changes in the skin or mucous membranes, back pain, and renal colic. You should inform your doctor immediately if you notice these signs of disease activity. However, these symptoms may not always be due to IBD activity. Often, they

may be due to dietary errors (for example, diarrhea due to food intolerance) or acute bowel infections, which of course may also occur in patients with IBD.

5. Learn about dietary measures you can take and consult a dietician.
6. Get informed about your disease and about your individual situation. It may also be helpful to keep your own records because in the case of long-term disease, it is likely that many different physicians will be involved in your care, working independently from one another. Keep records of the examinations you have undergone, as well as any surgical reports. Important information to record includes the addresses of places where you had surgery or examinations, and when each of the procedures you had were done, plus the extent of these procedures. You yourself should be aware of how extensive your disease is and what treatment methods have already been tried. Also note any side effects or medication intolerances.

Glossary

Abscess	Encapsulated accumulation of pus due to inflammation that is often caused by bacteria
Anemia	A condition in which there is a deficiency of red blood cells or of hemoglobin in the blood
Colon	Large bowel
Duodenum	The first segment of the small bowel
Dysplasia	Abnormal development of tissue. Dysplasia may occur in different degrees of severity and may be considered a precursor of cancer (particularly cancer of the bowel in this context)
Erythema nodosum	Violet-reddish thickening of the skin, usually on the arms or legs
Fistula	An abnormal, “short circuit” connection between two bowel segments, between the bowel and the bladder or vagina, or between the bowel and the skin, occurring as a result of inflammation
Ileocecal valve	A valve-like structure located directly at the transition between the last segment of the small bowel (ileum) and the start of the large bowel (colon)

Ileum	Final segment of the small bowel
Ileus	Obstruction of the bowel caused by narrowing (stenosis) or paralysis
Immuno-suppression	A treatment that inhibits the body's immune system (defense system)
-itis	A suffix that refers to inflammation: e.g. colitis = inflammation of the colon, hepatitis = inflammation of the liver (Greek term for liver = hepar)
Jejunum	Middle segment of the small bowel
Osteoporosis	Loss of bone tissue or change in the overall shape of the bone. This leads to a reduction in the mechanical resilience of the bone and to an increased susceptibility to bone fractures
Perforation	A hole in the wall of the bowel
Peritonitis	Inflammation of the membrane lining the inner surface of the abdomen
Pouch	Reservoir for stool that is surgically created from a bowel loop
Relapse	Return of disease activity, renewed flare-up of inflammatory bowel disease

Stenosis	A narrowing of the bowel that usually occurs as a result of inflammation. Over time, long-lasting inflammation can result in scar-tissue formation that makes the narrowing permanent
Stricture	Another word for stenosis, but the word “stricture” always refers to a narrowing of the bowel that has become permanent due to scarring
Stricturoplasty	A surgical procedure for the treatment of strictures in the bowel that does not require the narrowed area of the bowel affected by stenosis to be cut out
Subileus	Incomplete intestinal obstruction
Tumor necrosis factor (TNF)	A transmitter substance in the human body that plays an important role in inflammatory processes
Toxic megacolon	Complication occurring mostly in patients with ulcerative colitis and involving an acute dilation (ballooning) of the colon
Ulcer	An open sore

Further information for patients with inflammatory bowel diseases:

- Rectal treatment for inflammatory
bowel disease (S97e)
29 pages
- Diet and Nutrition in Crohn's Disease
and Ulcerative Colitis
Important Questions – Real Answers (S84e)
63 pages
- Crohn's disease and its associated
disorders (S85e)
44 pages
- Corticosteroid therapy in inflammatory
bowel diseases (BU80e)
32 pages

These brochures can be ordered from
Falk Foundation e.V. or the local Falk partner.

FALK FOUNDATION e.V.



Leinenweberstr. 5
79108 Freiburg
Germany

www.falkfoundation.org



Dr Falk Pharma Australia Pty Ltd
Suite 10.01, 815 Pacific Highway
Chatswood, NSW 2067
Tel: 1800 DRFALK (1800 373 255)

FALK FOUNDATION e.V.



Leinenweberstr. 5
79108 Freiburg
Germany