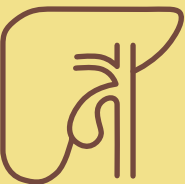
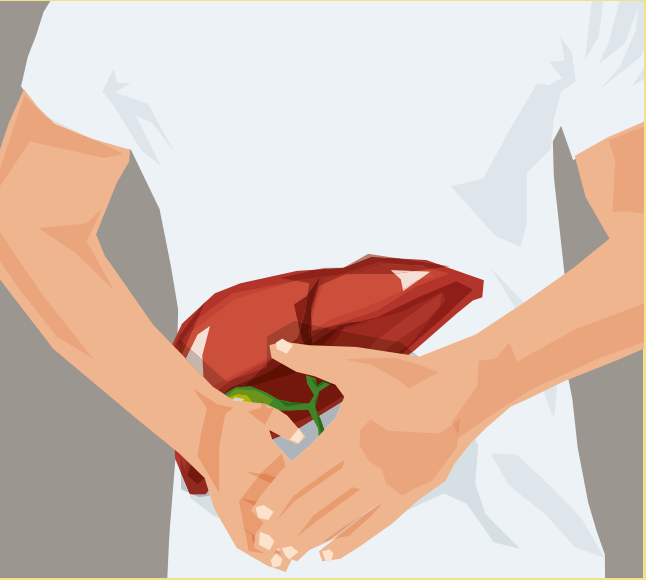


Primary sclerosing cholangitis (PSC)



Publisher

FALK FOUNDATION e.V.



Leinenweberstr. 5
79108 Freiburg
Germany

www.falkfoundation.org

© 2020 Falk Foundation e.V.
All rights reserved.

1st edition 2020

Primary sclerosing cholangitis (PSC)

Compiled by
Prof. Dr. Thomas Berg and
Toni Herta, Leipzig

Acknowledgement

We are grateful to the author of the previous edition of this booklet, Prof. Dr. Ulrich Leuschner, Praxisklinik für Gastroenterologie, Frankfurt am Main, Germany.

Address of the authors

Prof. Dr. Thomas Berg
Toni Herta
Sektion Hepatologie
Klinik und Poliklinik für Gastroenterologie
Universitätsklinikum Leipzig
Liebigstr. 20
04103 Leipzig
Germany

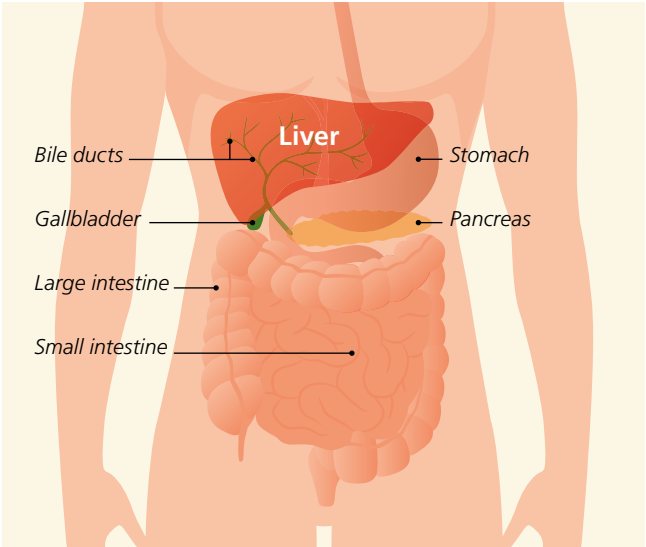
The liver	4
Structure and function	4
What is primary sclerosing cholangitis?	8
How common is PSC?	9
How does the disease progress?	9
What are the different forms of PSC?	10
Is there a genetic test that can predict the likelihood of the disease?	11
What are the signs of PSC?	12
How do doctors diagnose PSC?	14
What are the main physical signs of PSC?	14
Which blood tests are required?	14
Is endoscopic imaging of the bile ducts necessary in order to diagnose PSC?	16
Does a liver biopsy need to be taken?	17
How does PSC progress?	18
What other conditions are typically associated with PSC?	18
What complications may occur during the course of PSC?	20
Are PSC patients at a higher risk of cancer?	22
How is PSC treated?	25
Which medications can be used to treat PSC?	25
What are the endoscopic treatment options?	26
How can the symptoms of the disease be reduced?	26
When is liver transplantation required?	29
What is a PSC overlap or variant syndrome?	30
Summary	31

The liver

The liver is made up of several different lobes: a larger right lobe, a smaller left lobe, and two other small lobes (the quadrate and caudate lobes). It can also be subdivided into eight segments. The liver is located in the right upper quadrant of the abdomen, directly below the diaphragm and the bottom of the rib cage, which makes it difficult to feel by hand. It is surrounded by a capsule of connective tissue.

The liver is the largest and most complex metabolic organ in the body, weighing 1.5–2 kilograms and carrying out more than 500 different functions. It typically holds about 10% of the total volume of blood in the body, and up to 1.4 liters of blood are pumped through it each minute, which requires extraordinary filtering capabilities. The liver is thus the main organ in the body for storage, detoxification, and excretion, which is why it also plays an important role in breaking down alcohol and medications. It is also important for metabolizing protein, fats, and carbohydrates, for protecting the body from infection, and for maintaining a balance of minerals, vitamins, and hormones.

However, the liver can become damaged when breaking down toxic chemicals, although this damage typically does not impact its function for many years. Liver damage usually accumulates over time as a result of repeated exposure. At the same time, the liver is an organ that is capable of regeneration. This makes it possible to donate a portion of the liver, since it can then grow back to its original size.

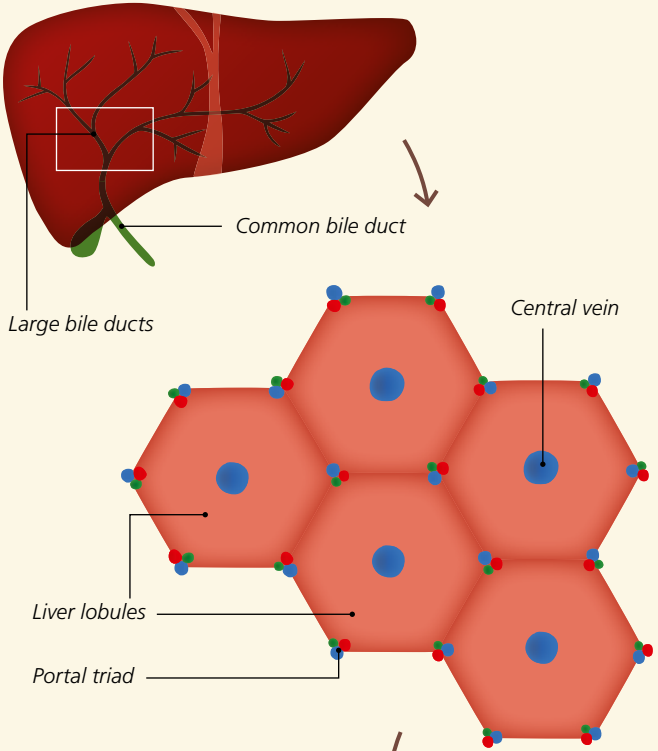


Functions of the liver

- **Metabolic and synthetic functions**
including proteins, carbohydrates, fats, clotting factors, vitamins, trace elements
- **Glandular functions**
including production of bile
- **Storage functions**
including glycogen, iron
- **Detoxification**
including harmful substances
- **Breakdown and excretion**
including various metabolic products, alcohol, medications

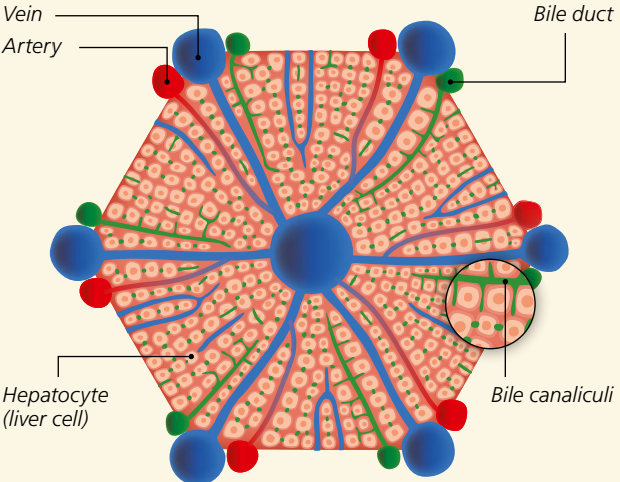


Structure of the liver, liver lobules, and bile ducts



Liver lobule


Blood vessels




Lobules represent the smallest structural subunit from a functional perspective, and are comprised of highly specialized hepatocytes (liver cells) arranged in a ring-like form. Very small blood vessels (sinusoids) cross through the lobules and allow the exchange of substances between the blood and the liver. The lobules also contain very small bile channels known as bile canaliculi. These channels surround the hepatocytes before merging into small bile ducts, which themselves merge to form larger bile ducts. Hepatocytes metabolize nutrients from the bloodstream not only in order to store them, but also to produce substances that are crucial for the body.

In particular, they **produce 700–1,500 ml of bile per day**, which flows out through

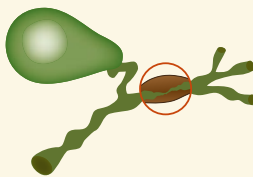
the bile canaliculi and bile ducts into the gallbladder, where it is stored between meals. The gallbladder is located below the right lower lobe of the liver near the front of the abdomen. Following the ingestion of food, it secretes bile by contraction, which then travels through the common bile duct into the small intestine, where it promotes the digestion of food, particularly of fats.



When the bile ducts – especially the large bile ducts – are remodeled and damaged by inflammation, diseases such as primary sclerosing cholangitis (PSC) may develop.



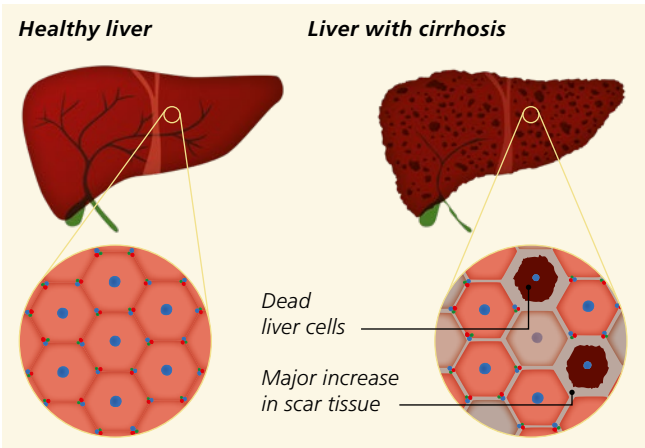
Normal bile ducts



Structure of a bile duct damaged by inflammation

What is primary sclerosing cholangitis?

Primary sclerosing cholangitis (PSC) is a chronic autoimmune disease of the liver that is characterized by inflammatory scarring of the bile ducts. This scarring leads to the prominent narrowing (strictures) of these ducts that resembles “beads”. The disease primarily affects the larger bile ducts inside and outside the liver, although the patterns of inflammation can vary dramatically from one patient to the next (see page 10). In typical cases, the inflammation leads to strands of tissue scarring around the bile ducts that resemble an onion skin. As the proportion of this scar tissue increases, the bile ducts gradually become constricted, leading to a blockage of bile (known as cholestasis). Left untreated, this inflammatory damage begins to target the tissue of the liver. The end stage of the disease is cirrhosis of the liver. White blood cells from the body’s immune system play an important role in the disease by attacking both the



bile ducts and the liver tissue. The disease is thought to be caused by interactions between hereditary (genetic) and environmental factors. Close coordination between the gut and the liver appears to be crucial for the development of PSC. The majority of PSC patients also have

inflammatory bowel disease (IBD). In rare cases, IBD may also develop during the course of PSC (see page 18). The inflamed intestinal walls of IBD patients appear to be more permeable to certain bacterial components that activate the immune system within the intestinal wall. It is believed that components from both bacteria and the body are transported from the intestinal walls to the liver by the portal vein (the vessel that collects blood from the intestines and transports it to the liver). Once in the liver, these components then travel to the bile ducts, where they may trigger or maintain the inflammation that causes PSC.

**Autoimmune disease/
autoimmunity:**

A pathological reaction by the immune system to the body's own tissues.
Adjective: *autoimmune*

i

How common is PSC?

PSC is a rare disease. The global rate of the disease is believed to be less than 16 per 100,000 people. The disease afflicts men three times as often as women. The average age at which the disease starts is less than 40 years old, and some patients even get the disease as children.

How does the disease progress?

PSC is a progressive disease whose rate of progression can differ greatly from patient to patient. Despite intense and promising research, the treatment options for PSC remain unsatisfactory. The average time between diagnosis and the need for liver transplantation is about 20 years. Nonetheless, PSC can be cured by liver transplantation in most patients.

What are the different forms of PSC?

PSC is a highly variable disease that can manifest in several different presentations. These forms differ from one another in terms of their pattern of inflammation of the bile ducts, their risk of cancer, and their prognosis. These differences in presentation are likely due to specific genetic mutations, and research is currently focusing on identifying such mutations.

The classic form of PSC is characterized by inflammation of the larger bile ducts, and is usually (60–80% of PSC patients) accompanied by IBD (most often ulcerative colitis). In this form, both the bile ducts inside and outside the liver (running between the underside of the liver and the junction with the duodenum) are affected. 50% of patients have major narrowing (stricturing) of the bile ducts. This degree of narrowing is associated with an increased risk of bacterial infection of the bile ducts (called bacterial cholangitis) and of bile duct cancer (cholangiocarcinoma), which in turn is associated with a poorer prognosis.

Another rare form of PSC affects the larger bile ducts in the absence of IBD. This form afflicts men and women equally, and usually develops in older patients (around age 50). The absence of IBD reduces the risk of cancer of the bile ducts, liver, and gut, and thus has a more favorable prognosis.

PSC of the small bile ducts in the liver represents a special form of PSC. Although these patients present with the typical clinical, laboratory, and microscopic (histological) signs of PSC (see page 14), their bile ducts appear normal by imaging procedures. It is thought that PSC is restricted to the small bile ducts in about 10% of diagnosed patients. This special form of PSC has a much better prognosis than classic PSC, in which the larger bile ducts are also affected. The risk of bile duct cancer is much lower, and bacterial infections of the bile ducts are not observed. Liver transplantation is more rare for

patients with this form of PSC, and those who do need transplantation typically require it at a much later time point. Furthermore, these patients typically respond much better to pharmaceutical treatment with ursodeoxycholic acid (UDCA, see page 25).

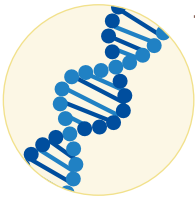
Another special form of the disease is PSC associated with autoimmune hepatitis. This combined condition is called overlap syndrome (or variant syndrome) and is described in the last section (see page 30).

Bile duct cancer:

Subgroup of malignant cancers (medical term cholangiocarcinoma) that arises from bile duct cells (cholangiocytes). It can develop in both the small and large bile ducts.

i

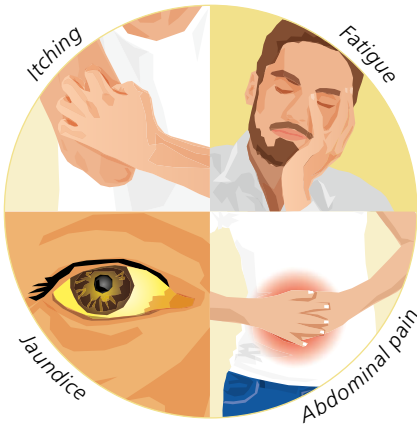Is there a genetic test that can predict the likelihood of the disease?



The role of genetic factors in the development of PSC is illustrated by the fact that first-degree relatives of PSC patients have a 100-fold higher risk of PSC than does the population at large. In recent years, a number of genes have been identified that, when mutated, can influence the risk of developing PSC or the form of the disease. Despite this, there is (as yet) no genetic test that can predict the likelihood of developing the disease.

What are the signs of PSC?

Only half of all PSC patients exhibit the typical symptoms of the disease at the time of their diagnosis (see table 1). Patients often have a prior diagnosis of inflammatory bowel disease, and are then suspected of having PSC after a routine laboratory test reveals elevated levels of liver enzymes – especially enzymes suggestive of a bile duct disorder (AP and GGT, see page 14).



The typical signs of PSC include decreased energy and constant fatigue.

However, these may also be signs of numerous other conditions. Itching

(pruritus), pain in the right upper abdomen, or major unintentional weight

loss may also be the initial

signs of PSC. Fever with chills is indicative of secondary bacterial infection of the bile ducts, and is often seen in the advanced stages of the disease when major constrictions (dominant strictures) of the large bile ducts have formed. A yellow discoloration of the eyes or skin (jaundice) is also an initial sign of PSC in rare cases. Jaundice may not only be an indication of scarring and narrowing of the bile ducts, but may also be caused by gallstones. Gallstones are more common in patients with PSC, and may even occur at early stages of the disease in some situations.

In addition, patients with IBD and PSC may also experience symptoms that include abdominal pain of varying intensity and bloody or watery diarrhea. IBD may also be accompanied by joint or spinal symptoms, recurrent conjunctivitis, open wounds around the anus (anal fistulas), or dough-like, red swelling of the legs (erythema nodosum). However, the bowel disorder accompanying PSC may also be only of minor severity, and a patient may not notice the condition until asked by his or her doctor. There is no link between the severity of an inflammatory bowel disease and the severity of PSC.

Table 1: Symptoms that may indicate PSC when occurring together

- **Fatigue**, exhaustion, decreased energy
- **Itching** (pruritus)
- **Pain upon pressure** in the right upper abdomen
- **Weight loss**
- Slightly elevated body temperature or **fever**
- **Yellow discoloration of the skin and eyes** (jaundice)

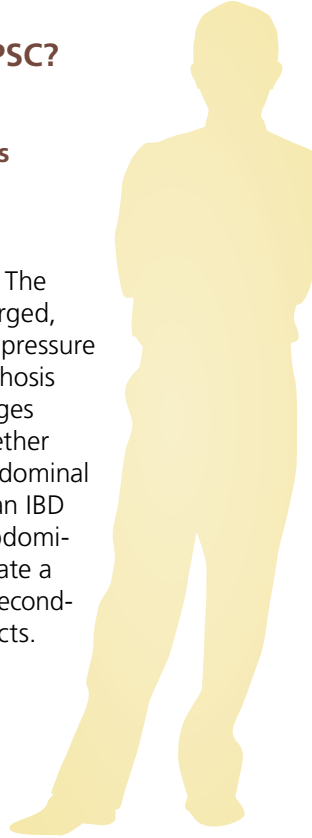How do doctors diagnose PSC?

What are the main physical signs of PSC?


In the early stages, PSC is often not detected by a physical examination. The liver or spleen may be palpably enlarged, or slight pain may be noticed when pressure is applied over the liver. Signs of cirrhosis of the liver are observed at later stages (see table 4). Patients with PSC together with IBD may experience intense abdominal pain on pressure, especially during an IBD flare, and may also have clucking abdominal sounds. Fever or chills may indicate a flare of the bowel disease or even a secondary bacterial infection of the bile ducts.

Which blood tests are required?

Blood levels of alkaline phosphatase (AP) and gamma-glutamyl transferase (GGT), both of which reflect bile blockage (cholestasis), are particularly high in PSC patients. On the other hand, the levels of transaminases (alanine aminotransferase [ALT] and aspartate aminotransferase [AST]) are typically less elevated and may even be normal. Elevated blood levels of bilirubin point to an advanced stage of the disease or additional complications (such as dominant strictures in the bile ducts, bile duct cancer, or gallstones) with major cholestasis. Anti-mitochondrial antibodies (AMA), which are relevant for another cholestatic disease called primary biliary cholangitis (PBC), cannot be detected in PSC patients.



However, circulating antibodies (called pANCA) that target neutrophils (a type of specialized immune cell) are often found in blood, and may indicate the presence of PSC. Autoantibodies targeting the cell nucleus (anti-nuclear antibodies, abbreviated as ANA) or smooth muscle fibers (abbreviated as SMA) are also frequently detected. However, these antibodies are neither the trigger for nor proof of the disease; indeed, they are also found in a number of other autoimmune diseases but also in healthy subjects. As with all cases of liver cirrhosis, the end stage of PSC is characterized by a reduction in platelets (thrombocytes) since these cells are less produced in the bone marrow and are retained and degraded by the enlarged spleen. The blood levels of the bile dye bilirubin increase, leading to a condition called jaundice (icterus), while the production of protein and blood clotting factors by the liver decreases.



Antibodies: Proteins called *immunoglobulins* (Ig) that are produced by specialized cells in the immune system. *Immunoglobulins* contain binding sites that are highly specific for the components of other proteins. These components may include surface structures on foreign cells, bacteria, fungi, viruses, pollen, medications, or food components. After binding to a target like bacteria, the *immunoglobulins* can trigger additional processes that destroy the bacteria. In rare cases, the body can also produce antibodies that target its own structures; these are called *autoantibodies* (from the Greek *αὐτο-* (auto-), meaning “self”).

Is endoscopic imaging of the bile ducts necessary in order to diagnose PSC?

The most crucial step in diagnosing PSC is visualization of the bile duct system both inside and outside the liver. Ultrasound examinations can usually detect dilated bile ducts within the liver with confidence. Assessment of the bile ducts outside the liver requires an experienced examiner. Thickened duct walls and bulges in the bile ducts or changes to the gallbladder (such as thickened walls, polyps, or stones) may be visible. Swollen lymph nodes are often found near the structure called the porta hepatis, which is where the bile ducts emerge from the underside of the liver. Nonetheless, ultrasound examinations are often normal during early stages of the disease. If the findings are uncertain, the bile ducts, gallbladder, and the lymph nodes near the porta hepatis can also be examined by endoscopic ultrasound.

Endoscopic retrograde cholangiopancreatography (ERCP) was considered to be the gold standard for imaging the bile ducts for many years. In this method, an endoscope is inserted through the esophagus and the stomach into the duodenum similar to a gastroscopy. For ERCP, the endoscope is guided to the junction of the common bile duct and the intestines. There, a catheter contained in the endoscope injects an X-ray contrast medium directly into the bile ducts. By taking an X-ray image of this region immediately after the injection, a detailed image of the bile ducts can be obtained. PSC typically appears as numerous short stretches of bile duct narrowing alternating with bulges and normal sections of bile ducts (“beads”). These dominant strictures in the bile ducts must typically be stretched by endoscopy (see page 26). Although ERCP does allow treatments to be carried out on the bile ducts together with imaging, it also poses the risk of complications such as infection of the pancreas (pancreatitis) or of the bile ducts by bacterial contamination from the intestine (bacterial cholangitis).

Due to the risks of ERCP described above, magnetic resonance cholangiopancreatography (MRCP) is currently the preferred method for confirming a diagnosis of PSC. This procedure is carried out similar to normal magnetic resonance imaging (MRI) of the upper abdominal region. Collecting specific sequences allows a detailed image of the biliary tree to be obtained. This method does not require the use of X-rays, and is therefore much safer than ERCP. However, if PSC is highly suspected (especially small-duct PSC) but the bile duct changes typical of PSC are not observed by MRCP, then ERCP or liver biopsy (see below) should be performed. Some of the early changes to the bile ducts that occur during the initial stage of PSC might not be visible by MRCP, but can be detected using ERCP. MRCP is usually not an option for patients with pacemakers that are not MRI-compatible, for patients with other metal permanently situated in their bodies, or for claustrophobic patients.

Stricture: Narrowing of a tube-shaped hollow organ such as the bile ducts.

i

Does a liver biopsy need to be taken?

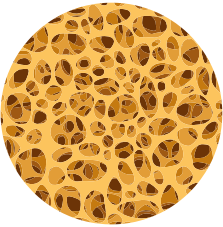
It is usually not necessary to confirm a diagnosis of PSC by microscopic examination of tissues, except for patients with suspected small-duct PSC or suspected PSC together with autoimmune hepatitis (see page 30). In these cases, an ultrasound-guided tissue biopsy is taken using a fine needle under local anesthesia.

How does PSC progress?

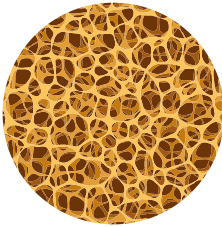
PSC usually has a variable course. Patients with inflammation of the larger sized ducts are at a particularly high risk of recurring bacterial infections of the bile ducts, liver cirrhosis with hypertension of the portal vein, and cancer. The average time between the initial diagnosis of PSC and liver transplantation is presently about 20 years.

What other conditions are typically associated with PSC?

PSC may be accompanied by weakened bones (osteoporosis), fatty stools, and deficiencies in fat-soluble vitamins (see page 29), as well as a number of associated autoimmune diseases (see table 2).



Normal bone



Osteoporosis

Inflammatory bowel disease

The vast majority (about 70%) of PSC patients also suffer from inflammatory bowel disease (IBD). PSC is usually diagnosed after IBD, but in some cases an initial diagnosis of PSC may actually be the first clue of an undiagnosed case of IBD. Conversely, 5–7% of IBD patients will develop PSC. The majority of these patients have ulcerative colitis (about 80%), while many fewer have Crohn’s disease (about 10%) or a different form of IBD that cannot be precisely classified (about 10%).

Table 2: Autoimmune diseases that can accompany PSC**Common:**

- Inflammatory bowel disease (IBD)
- Autoimmune hepatitis

Less common:

- Hashimoto's thyroiditis
- Type 1 diabetes
- Psoriasis
- Rheumatoid arthritis
- Vitiligo (loss of skin color)
- Inflammation of small blood vessels (granulomatosis with polyangiitis)
- Ankylosing spondylitis (spinal disorder)

In many of these IBD patients, inflammation is found in very specific segments of the gut. Typically, the entire large intestine (especially the right side) and its junction with the small intestine (backwash ileitis) are affected. In patients with PSC and ulcerative colitis, the end of the large intestine (rectum) is often not inflamed, which differs from the situation in ulcerative colitis patients without PSC. For this reason, the combination of ulcerative colitis and PSC is sometimes thought to represent a unique condition. The intestinal symptoms of this condition may be very mild and even go unnoticed. Hence, when PSC is diagnosed in a patient without a history of inflammatory bowel disease, a complete colonoscopy must be performed, with tissue biopsies collected from several different sites in the gut.

What complications may occur during the course of PSC?

Bacterial infection of the bile ducts

Bacterial infection of bile ducts scarred by PSC (called bacterial cholangitis) represents a potentially life-threatening complication of the disease. Infections are usually caused by bacteria from the small intestine, which are transported to the bile either naturally (for example by blood in the portal vein) or through endoscopic procedures in the bile ducts. Because PSC slows the flow of bile, these bacteria can then reproduce in the bile (which is normally sterile) and trigger severe inflammation of the bile ducts. Mixed infections caused by several different types of bacteria are common. The classic symptoms of cholangitis (fever with chills, pain in the right upper abdomen, and jaundice) are called “Charcot’s triad”. However, bacterial cholangitis caused by PSC often does not present with these classic symptoms (see table 3). In these situations, the blood levels of inflammation markers are usually elevated. Increased blockage of bile (dilated bile ducts) may be observed by ultrasound of the liver.

Table 3: Symptoms that may indicate bacterial cholangitis


- **Increased** itching (pruritus)
- **Increased** yellow discoloration of the eyes and skin (jaundice)
- Dark urine, pale stools
- Nausea and vomiting
- Slightly elevated body temperature or fever, often with chills
- Intense night sweats
- Pain in the right upper abdomen

Bacterial cholangitis is a medical emergency that must be treated immediately. It is treated with intravenous antibiotics and endoscopic management of any blockage in bile flow (such as dominant strictures or gallstones) using ECRP (see page 16).

Cirrhosis of the liver


The signs and complications of liver cirrhosis during the end stage of PSC are listed in the table below:

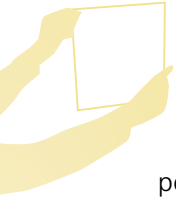Table 4: Complications of liver cirrhosis

- | | |
|---|--|
| – Bleeding from esophageal, gastric or rectal varices, occasionally also from ulcers in the stomach or duodenum |  |
| – Ascites | |
| – Cognitive dysfunction triggered by liver disease (hepatic encephalopathy) | |
| – Clotting disorders with higher risk of bleeding | |
| – Edema (such as swollen lower legs) resulting from low levels of protein | |
| – Kidney dysfunction caused by liver cirrhosis (hepatorenal syndrome) | |
| – Greater susceptibility to infections | |
| – Muscle atrophy in the arms and legs (sarcopenia) | |
| – Liver cancer (hepatocellular carcinoma) | |

Are PSC patients at a higher risk of cancer?

PSC is associated with a much higher risk of certain kinds of cancer. About 10–15% of PSC patients develop bile duct cancer, and about half of those patients develop the cancer within the first year after their PSC diagnosis. Unfortunately, it is very difficult to detect bile duct cancer, as it is often not possible to differentiate between benign and malignant narrowing of the bile ducts using imaging procedures. Cancer is usually suspected in patients whose PSC progresses rapidly, who gain significant weight, or who have increased itching or yellow discoloration of their skin and eyes. Should any of these indications occur, an immediate MRCP examination is necessary to visualize the bile ducts. If a dominant stricture of the bile ducts is observed, or if a known stricture has become even more narrow than in the previous examination, ERCP must be performed. Tissue samples should be collected from the suspicious areas using sample forceps. Samples can also be collected from longer segments of bile duct using a small brush. These tissue and cellular samples should then be tested for the typical features of cancer (malignancy criteria). If none of the typical features of cancer are detected in these tests but strong suspicion of bile duct cancer remains, direct endoscopy of the bile ducts (called cholangioscopy) may be performed. In this technique, a very thin endoscope is inserted into the bile ducts, usually using an ERCP device. The tip of this endoscope contains a high-resolution camera. This procedure can be used to collect samples more directly from suspicious areas. Such precision probably increases the success rate of this method, although the research on this topic is not conclusive. In any case, if bile duct cancer cannot be detected yet cancer is still suspected, these tests should be repeated

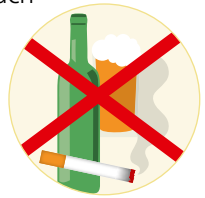



in a timely manner. MRCP follow-ups are generally recommended at least every 12–24 months. Levels of the bile duct cancer tumor marker (CA19-9) can also be measured periodically, although the predictive value of this marker is low as CA19-9 also increases in patients with cholestasis in the absence of cholangiocarcinoma. Tumor markers are proteins found in blood that indicate specific types of cancer when present at higher levels.

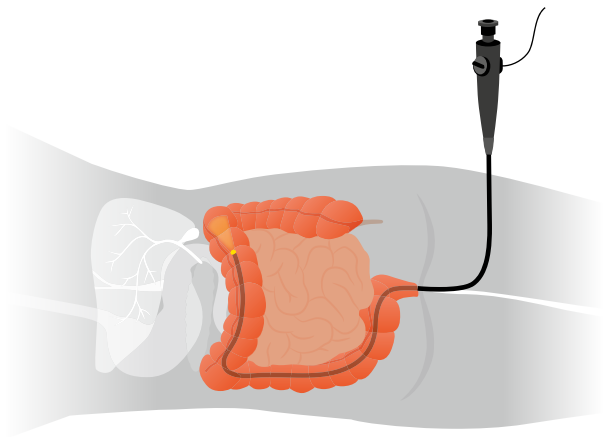
Malignant cancer can also develop within the gallbladder. PSC patients shall undergo ultrasound examinations for this type of cancer at least once per year. If polyps with a diameter greater than 8 mm are detected within the gallbladder, it shall be removed as soon as possible. However, in light of the fact that even smaller polyps and gallstones also present a risk of developing cancer in patients with PSC, gallbladder removal is also recommended in either of these scenarios.

About 2% of all patients with PSC will develop liver cell cancer (hepatocellular carcinoma). To keep this risk from increasing even further, lifestyle habits such as smoking or regular alcohol consumption should be stopped. Ultrasound examination of the liver together with testing for the tumor marker AFP (alpha-fetoprotein) is recommended every six months for patients with advanced PSC.



The risk of developing a malignant cancer of the pancreas (pancreatic cancer) also appears to be higher in patients with PSC. However, this risk is still much lower than the risks of the other forms of cancer discussed above. Therefore, regular testing for pancreatic cancer is currently not (yet) recommended.

The risk of colorectal cancer – cancer of the gut – is high, especially in patients who also have IBD. Since the risk of colorectal cancer is generally high among the population at large, it is accordingly also the most common form of cancer in PSC patients. In patients who have PSC together with IBD, colorectal cancer usually develops at a much younger age, is diagnosed at a later stage, and is frequently located on the right side of the large intestine. Colonoscopy as well as the collection of tissue samples from suspicious areas should be performed every year for patients who have PSC together with IBD. This allows the colorectal cancer to be detected and possibly completely removed at a very early stage. Patients with PSC but not IBD should have a colonoscopy every 3–5 years.



How is PSC treated?

Which medications can be used to treat PSC?

There are two types of treatment: direct treatment of PSC itself, and treatment of the symptoms and conditions associated with PSC. Treating PSC directly using medications is a difficult task, as no effective medications are currently available. Although PSC is considered to be an autoimmune disease, steroid therapy (using drugs called “corticosteroids”) or therapy using classic inhibitors of the immune system (immunosuppressants) is not effective. This is apparently due to the fact that the formation of scar tissue (fibrosis) plays a greater role in this disease than does inflammation.

The benefits of ursodeoxycholic acid (UDCA) for the treatment of PSC remain controversial. Several studies have shown that UDCA prescribed at moderate doses of 15–20 mg/kg body weight per day can indeed improve laboratory test results and in some cases even liver histology findings. However, there is no conclusive evidence to date that UDCA can extend the time until liver transplantation is required. According to the current consensus, higher doses of > 28–30 mg/kg body weight per day should not be taken, since these doses may actually negatively impact the course of the disease, especially in patients whose PSC is in an advanced stage. Even though the studies are not always in agreement, it is still assumed that UDCA can have a positive effect on the prognosis of PSC, especially if treatment is started early. The general trend of treating PSC patients with UDCA is also thought to be the reason why the long-term rates of bile duct cancers in PSC patients have been decreasing over the past few decades. Taking UDCA at moderate doses also most likely reduces the risk of colorectal cancer in PSC patients with IBD. The “European Association for the Study of the Liver” (EASL) therefore recommends that doctors consider prescribing UDCA at moderate doses to PSC patients, especially those patients with a long

history of IBD, with prior colorectal cancer, or with a family history of colorectal cancer.

Research is also being conducted into new drugs with beneficial effects on bile acid metabolism.

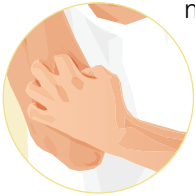What are the endoscopic treatment options?

Dominant strictures in the bile ducts should be re-opened using an endoscopic procedure called balloon dilation. In this procedure, an endoscope is inserted into the mouth and advanced up to the junction of the common bile duct and the intestine. From here, a small catheter with a balloon at its tip is inserted into the bile duct. The balloon is then expanded by injecting fluid into it. Studies have shown that repeated stretching of dominant strictures can slow the damage to the liver caused by the blockage of bile (cholestasis) and can have positive effects on symptoms such as itching. The optimal interval between balloon dilations is not known, so doctors and patients should set their own schedule for the procedure. Plastic tubes (stents) can also be inserted into the bile ducts, but this should only be performed in exceptional cases due to the higher rate of complications (such as stent blockage and bacterial cholangitis) as compared to balloon dilation. It is also crucial that tissue samples be collected from dominant strictures so that bile duct cancer can be detected at an early stage.

How can the symptoms of the disease be reduced?

Treating PSC with UDCA usually does not significantly alleviate the symptoms of the disease, which patients often perceive as being very unpleasant. One initial requirement for effective treatment is the systematic documentation of the symptoms (using standardized questionnaires your doctor has), which can be repeated at regular intervals.

A number of medications are available to treat the symptom of itching, which may be very severe in some situations. The skin should be kept moist using



natural skin care products. A cold shower may (temporarily) alleviate itching, since it is frequently exacerbated by warmth.

A comprehensive allergy test should be performed to rule out other possible causes of the itching. In extreme cases, alternative forms of treatment may be at-

tempted at specialized centers, including a type of dialysis called albumin dialysis, using a nasal probe to drain bile, or whole-body UVB light treatment (phototherapy). If none of these treatment attempts work, the option of liver transplantation should be discussed.

Itching typically subsides within the first 24 hours after the transplantation. It is difficult to treat fatigue and exhaustion since no medications are currently available for these symptoms. However, patients should still attempt to remain physically active and engage in social contacts. Mild to moderate movement (for example walking, balanced exercises) may have beneficial effects on overall well-being.



It is crucial that other potential causes of fatigue and exhaustion be ruled out (such as hypothyroidism or a sleep disorder caused by itching). In contrast to itching, fatigue usually persists after liver transplantation.

If the production of pancreatic enzymes that cleave fat is also reduced (fatty stools), the fat content in the diet should be reduced to 40–50 g daily and easily digestible fats (such as those in margarine and oils) should be favored. If these changes are not enough, pancreatic enzyme tablets will need to be taken before each meal. A balanced diet combined with regular outdoor physical activity is crucial for preventing osteoporosis, which is a common early complication of PSC (see table 5).

Table 5: Treatment of osteoporosis due to PSC

- Outdoor physical activity
- Balanced diet
- Vitamin D₃, calcium
- Medications that promote bone growth

Only take calcium or vitamin D if there are confirmed indications of a deficiency (by blood test) or if osteoporosis has already begun (X-ray measurement of bone density by DEXA). If bone density drops below a certain level (T-score), treatment should be started with medications that promote bone growth.

Cholestasis may lead to reduced uptake of the fat-soluble vitamins A, D, E, and K from the intestines. However, a genuine vitamin deficiency is exceedingly rare and usually only occurs together with sustained jaundice (icterus) or liver cirrhosis. Vitamin supplementation must be performed by injection, since the intestines will also not be able to absorb vitamin tablets.



When is liver transplantation required?

If PSC progresses to liver cirrhosis or liver cell cancer, the option of liver transplantation should be taken into consideration. Unmanageable, recurring bacterial infections of the bile ducts also represent a medical indication for liver transplantation. On the other hand, liver transplantation is only rarely possible in cases of bile duct cancer and even then only after prior chemotherapy. This is because bile duct cancer, unlike liver cell cancer, is usually not cured by transplantation. Following liver transplantation, PSC may recur in the transplanted liver (up to 25% risk). All transplantation patients should receive further care at a specialized clinic. Despite these risks, the success rates of transplantation are usually very high.

What is a PSC overlap or variant syndrome?

About 10% of patients with PSC also exhibit signs of autoimmune hepatitis. This form of overlap syndrome (or variant syndrome) is particularly common among young patients and children. In patients with PSC, major increases in the levels of the liver enzymes ALT and AST (usually more than five times higher than the upper limit of normal) are warning signs of an overlap syndrome. The blood concentration of immunoglobulin G (IgG) is also usually elevated, and the autoantibodies typical of autoimmune hepatitis can be detected. A liver biopsy is required for diagnosis.

Treating an overlap syndrome requires a fair amount of experience. PSC should be treated according to the criteria discussed above, while autoimmune hepatitis must be treated with corticosteroids (such as prednisone, prednisolone or budesonide), usually together with an immunosuppressant (such as azathioprine). Long-term immunosuppressant therapy is usually necessary, since the condition typically relapses once the immunosuppressant is stopped. Frequent laboratory testing is necessary in order to detect a recurrence of the autoimmune hepatitis in a timely manner.

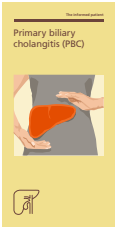i

Immunosuppression: A treatment strategy that addresses inflammation or transplant rejection by suppressing the immune system. Pursuing this goal also poses several risks, including infections (more common) and the potential development of malignant cancer (rare). The medications used for this strategy belong to a group called immunosuppressants.

Summary

- Primary biliary cholangitis is a **chronic autoimmune disease** of the bile ducts.
- It leads to **fibrotic scarring** of the larger bile ducts inside and outside the liver, which causes chronic blockage of bile due to the narrowing of the bile ducts.
- It **primarily affects men** and can even develop during childhood.
- PSC is accompanied by **inflammatory bowel disease** in 80% of cases.
- It is associated with a higher risk of **cancer** of the bile ducts, gallbladder, liver, pancreas, and intestines.
- There is currently no standard treatment for PSC.
- Pharmaceutical treatment with moderate doses of ursodeoxycholic acid (UDCA) may be attempted in certain circumstances.
- Dominant strictures of the bile ducts should be **stretched by endoscopy** (balloon dilation).
- Liver transplantation is required for patients with **cirrhosis of the liver, liver cell cancer**, recurrent bacterial **infections of the bile ducts** that cannot be managed by endoscopy, or uncontrollable itching.
- **The success rates for liver transplantation are very good.**

Additional available literature



Patient Information

Primary biliary cholangitis (PBC)

Authors: T. Berg, T. Herta

31 pages (U82EPBC)

This brochure can be ordered from
Falk Foundation e.V. or the local Falk partner.

FALK FOUNDATION e.V.



Leinenweberstr. 5
79108 Freiburg
Germany



Dr Falk Pharma Australia Pty Ltd
Suite 10.01, 815 Pacific Highway
Chatswood, NSW 2067
Tel: 1800 DRFALK (1800 373 255)

FALK FOUNDATION e.V.



Leinenweberstr. 5
79108 Freiburg
Germany